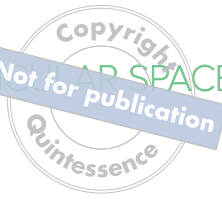

RESTORING THE INTRARADICULAR SPACE: ESTHETIC POST SYSTEMS



RESTORING THE INTRARADICULAR SPACE: ESTHETIC POST SYSTEMS

Douglas A. Terry, DDS

Private Practice
Houston, Texas

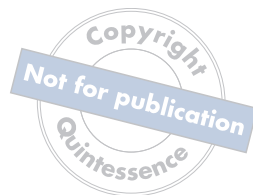Adjunct Professor
Department of Restorative Sciences
University of Alabama at Birmingham
Birmingham, Alabama

Professor Emeritus
Department of Restorative & Esthetic Dentistry
V.S. Dental College & Hospital
Rajiv Gandhi University of Health Sciences
Bengaluru, India

 **QUINTESSENCE PUBLISHING**

Berlin | Chicago | Tokyo
Barcelona | London | Milan | Mexico City | Moscow | Paris | Prague | Seoul | Warsaw
Beijing | Istanbul | Sao Paulo | Zagreb





Library of Congress Cataloging-in-Publication Data

Names: Terry, Douglas A., author.

Title: Restoring the intraradicular space : esthetic post systems / Douglas A. Terry.

Description: Batavia, IL : Quintessence Publishing Co, Inc, [2021] |

Includes bibliographical references and index. | Summary: "This book describes the biologic basis for restoring weakened teeth with post and core systems, focusing on how to do this conservatively and esthetically to maximize longevity"-- Provided by publisher.

Identifiers: LCCN 2020050058 | ISBN 9781647240561 (hardcover)

Subjects: MESH: Post and Core Technique | Dental Restoration, Permanent | Esthetics, Dental | Root Canal Therapy

Classification: LCC RK652.5 | NLM WU 515 | DDC 617.6/95--dc23

LC record available at <https://lcn.loc.gov/2020050058>



©2021 Quintessence Publishing Co, Inc

Quintessence Publishing Co, Inc
411 N Raddant Road
Batavia, IL 60510
www.quintpub.com

5 4 3 2 1

All rights reserved. This book or any part thereof may not be reproduced, stored in a retrieval system, or transmitted in any form or by any means, electronic, mechanical, photocopying, or otherwise, without prior written permission of the publisher.

Editor: Leah Huffman
Design: Sue Zubek
Production: Sue Robinson

Printed in China

CONTENTS



Foreword vi

Preface viii

Contributors x

1

ESTHETIC POST SYSTEMS 1

2

THE ADHESIVE DESIGN CONCEPT 61

3

CLINICAL APPLICATIONS FOR RESTORING
“COMPROMISED” ENDODONTICALLY
TREATED TEETH 127

4

CLINICAL APPLICATIONS FOR RESTORING
“END STAGE” ENDODONTICALLY
TREATED TEETH 207

Index 251

FOREWORD



There is a question I always ask myself, my students, and my colleagues: “What is our single most important responsibility as an oral health care provider?” While there may be various interpretations of our core duties, I always come to the same simple but resounding answer: “To help our patients keep their teeth as long as possible!”

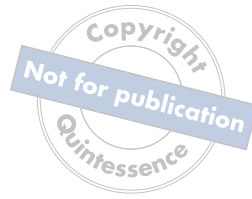To pursue this goal and preserve teeth, we have to emerge from the era of destructive dentistry, which dates back to times before resin bonding and adhesive protocols were available. Healthy tooth structure had to be sacrificed during preparation to accommodate restorative and prosthetic materials that relied solely on retention. The popularity of implant dentistry sometimes added to this destructive mindset when teeth were extracted and implants placed too early or inadequately, thereby accelerating the cascade of early tooth loss instead of following the core principle of preservation. The rush to the seemingly easiest but most destructive treatment options may lead to early tooth loss, bone and tissue resorption, peri-implantitis, and altered eruption of teeth next to implants that were placed in younger patients.

Several new studies agree that the recommended age when dental implants can be placed safely is going up and

up, making a strong case to preserve even severely damaged and endodontically treated teeth as long as possible. Don’t get me wrong: I have nothing against implants, and in many cases, they are the last and absolutely best resort to provide our patients with chewing function and esthetics. However, they are the last resort when everything else fails. And the argument I often hear that “implants last longer than teeth” is not only completely wrong but not even a logical argument for erring on the side of placing implants earlier instead of exploiting all resources to try and save a natural tooth. While some of that rationale may, sadly, be driven by convenience and economic aspects, I believe that the most important factors in the treatment-planning decision-making process are proper knowledge and information.

The most difficult treatment-planning decisions are related to the severely damaged endodontically treated tooth. The amount of misinformation on this topic is simply astonishing. What is the state of the scientific evidence on endodontically treated teeth and how to restore them? When should a post be placed? And in light of this era of minimally invasive and adhesive dentistry, what are the best materials and most current protocols for post and core placement, based on the science?

Douglas, author of many groundbreaking and bestselling books, has compiled a team of the most respected researchers and clinicians to answer these questions and provide clear guidance on a topic that seems to have been widely overlooked. *Restoring the Intraradicular Space:*



Esthetic Post Systems provides a detailed and scientific description of the evolution of post and core systems while offering a comprehensive view into all associated aspects, from general design criteria and the components of the post and core systems to post materials, adhesive bonding and luting agents, material selection, core buildup, and finally, the extracoronary restoration. The dilemma of preserving or replacing the compromised natural tooth is discussed in great detail with ample scientific support. Over 1,000 cited research studies are distilled into clear and meaningful guidelines for the clinician to select an appropriate system for the restorative management of endodontically treated teeth for each clinical situation. In well-known Douglas Terry manner, clinical protocols are illustrated meticulously and with stunning quality with over 800 photographs and figures.

To fulfill our responsibility to help patients keep their teeth as long as possible, understanding and selecting proper protocols, materials, and procedures to restore endodontically treated teeth is indispensable. While a comprehensive text on this topic was long overdue, *Restoring the Intraradicular Space: Esthetic Post Systems* is not only an exceptional

resource for the practicing dentist but a true masterpiece in its scientific rigor and clinical excellence. The captivating writing and superb clinical documentation make this an essential piece of literature for oral health care providers at any stage of their career. Congratulations Douglas and team—I am sure that your work will inspire countless colleagues and prevent many patients from losing their teeth too early. Thank you for that!

A handwritten signature in black ink, appearing to read "Markus B. Blatz".

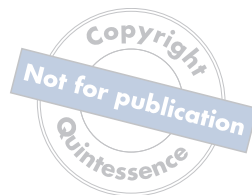Markus B. Blatz, DMD, PhD, Dr med dent habil

Chairman, Department of Preventive and Restorative Sciences

Assistant Dean for Digital Technologies and Professional Development

University of Pennsylvania School of Dental Medicine

PREFACE



Recently I read a comment by a dentist saying “every root has a chance.” This statement resonated with my philosophy because it is not only the tooth but also the alveolar and soft tissue architecture and the patient that deserve a chance. Over the last decade I have witnessed patients presenting with fractured teeth that were referred for removal and implant

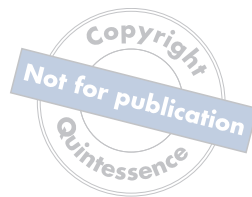placement. Upon discussion with them, it became clear that not everyone was given proper informed consent; some were offered only the one treatment option. So I would explain the how’s and why’s of every option, and then the patient could make the proper choice for their oral health. Individuals make better decisions when they are given all the potential options and the consequences of each.

A recent conversation with a young periodontist on my team further underscored this problem. He told me that his referring dentists do not try and save a given tooth with a post and core. In discussing this with my friend and colleague Dr Konrad Meyenberg in Switzerland, we considered that perhaps the reason was the lack of confidence clinicians have in the endodontic therapy and in their knowledge of proper adhesive protocol. This extraction-oriented, reconstructive mentality may be based on the clinicians’ misconception that endodontically treated teeth are considered inferior to implants in regard to long-term stability and retention. However, it has been demonstrated that endodontic and implant therapies have equivalent results when

the treatments are appropriately chosen and performed at a high level of expertise on well-maintained patients.

Throughout these chapters, I would like the reader to direct their attention to modern applications in the fields of endodontics, restorative dentistry, periodontics, and orthodontics. In the past two decades, dentistry has seen a paradigm shift in philosophy that has been guided by a greater understanding of science. Advancements in endodontic technology with the use of modern instruments and new equipment, biocompatible filling materials, and microsurgical techniques have allowed the clinician to visualize, identify, and treat complexities they could not have fathomed a decade before. Correspondingly, advancements in restorative material formulations, adhesive technology, and a better understanding of the methods to achieve a biologically stable, dentogingival interface through periodontal and orthodontic concepts have expanded the treatment possibilities for the patient, clinician, and technician. Furthermore, clinicians should not make treatment decisions based on their skill level alone but should refer or adopt an interdisciplinary approach when required for the management of more complex clinical scenarios.

These advances in all disciplines in the 21st century have increased the myriad opportunities available to discriminating patients and provided solutions to many of the endodontic, restorative, and esthetic challenges faced by the restorative team. This changing technology has allowed the clinician to treat many clinical challenges through simpler, more conservative, and more economical methods. This evolution in philosophy and science has resulted in a change in the trend for dental treatment. Thus, an awareness in the evolution of different disciplines in dentistry



combined with the common occurrence of misinformed patients coming for another opinion stimulated my team and me to develop this book. This philosophy of choosing the least invasive procedure and moving to a more invasive one if required over time is an ethical one. I hope the concepts in this book direct the clinician and technician to consider possibilities they had not imagined.

The text provides a detailed and scientific description of the evolution of the post and core system and the significance of the adhesive design concept when restoring the intraradicular post space. A detailed presentation is provided of the various applications and restorative techniques that I use on a daily basis with my patients for restoring the post space. The scientific data and microscopic illustrations are intertwined to provide clarity and evidence for these procedures. In addition, chapter 2 provides a detailed description of the light-curing unit (by Dr Richard Price) and the significance of understanding its mechanism for proper selection and use, which play an integral role in the adhesive design concept for achieving an optimal bonded interface. The third chapter demonstrates the information presented in the early chapters through illustrated case presentations while providing clinical applications for retaining the compromised tooth. The last chapter demonstrates clinical scenarios for the replacement and restoration of the nonrestorable endodontically treated tooth or the “end stage” tooth, while providing various treatment considerations and the critical factors that may play a role in the selection, outcome, and predictability of each of these treatment modalities.

Acknowledgments

As always, the inspiration for writing this book and sharing photographs of these procedures can be attributed to my dear patients, colleagues, and students around the world who have directed me on this journey. Compilation of this information would not have been possible without the dedication, persistence, and relentless hard work and long hours of my dear friend and personal assistant, Melissa Nix. My mother’s great ability to persuade patients to return for follow-up photographs along with her support and delicious dinners and desserts for the team have certainly been crucial for completing this project. Furthermore, this book would not have seen the light of day without the dedication, attention to detail, and organization and imagination of the Quintessence team. I would also like to express my gratitude to my team members who are my true friends—Dr John Powers, Dr John Burgess, Dr Ruhani Cheema, Dr Markus Blatz, Dr Susana Paoloski, Dr Gamid Nasuev, Alex Schueger, Olivier Tric, and Dr Richard Price. Also, I would like to thank my wonderful patients, without whom this project would not have been possible. Finally, I give special thanks to my Creator who instills passion in my life for everything I do and who makes me realize that teeth are simple in His hands but so complex in mine.

CONTRIBUTORS



Editorial Reviewers

John O. Burgess, DDS, MS
John M. Powers, PhD
Richard Price, BDS, DDS, MS, PhD
Susana B. Paoloski, DDS
Markus B. Blatz, DMD, PhD, Dr med dent habil

Scientific Reviewers and Contributors

Irfan Ahmad, BDS
Maciej Zarow, DDS, PhD
Norman Hicks

Clinical and Laboratory Contributors

Abdelrahman Awadin, BDS
August Bruguera, CDT
Victor Castro, CDT
Ruhani Cheema, BDS, MDS, MS
Jungo Endo, RDT
Manish Garala, BDS, MS
Kim S. Gee, DDS, MS
Gamid Nasuev, DDS, PhD
Wesam Salha, DDS, MSD
Alex H. Schuerger, CDT
Ritu Sharma, BDS, MDS
Riccardo Tonini, MD, DDS
Olivier Tric, MDT
Islam S. Zakzouk, BDS

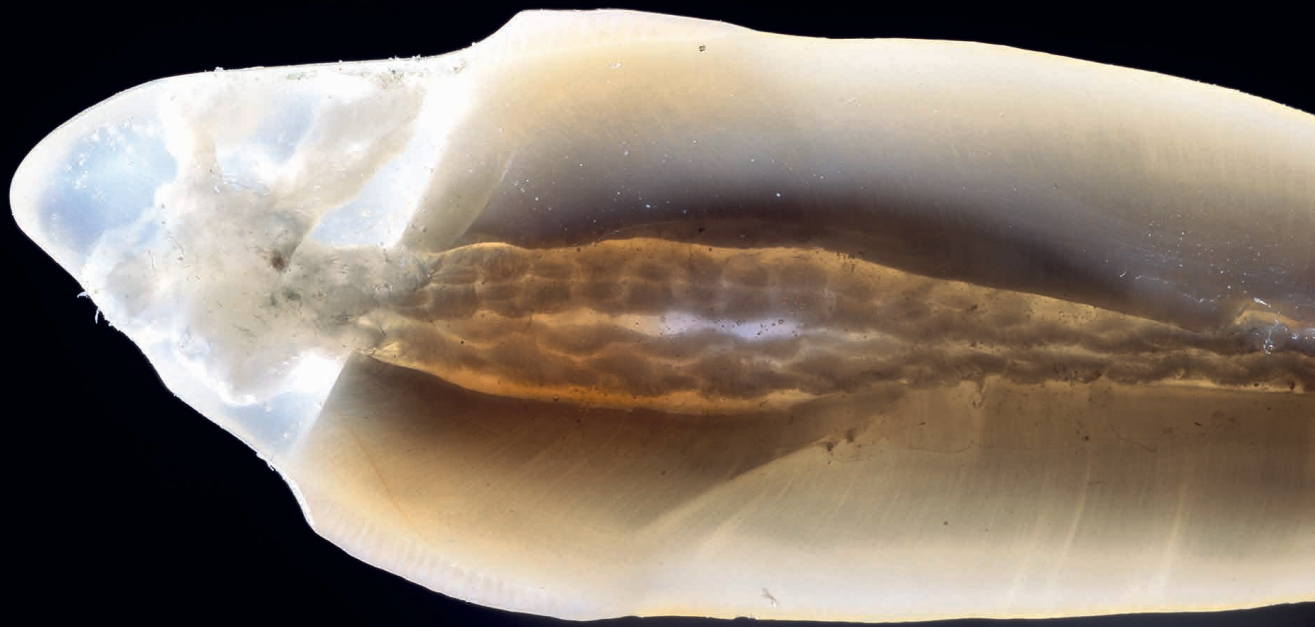[illegible]

“What is truth” is a question that has been asked by philosophers, scientists, and religious prophets for centuries.

better understanding and application. Relative truth conforms to logic and reality and can be interpreted differently by every person based upon their culture, religion, and life experiences. However, absolute truth requires each of us to search and discover something greater than ourselves.

God is the true essence of being and the absolute truth. The Bible describes the ultimate expression of truth in John 14:6: "I am the way, the truth, and the life."

Excerpt from Chapter

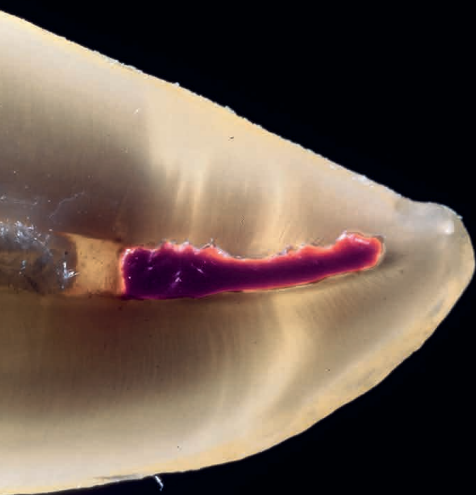

Photography by Irfan Ahmad, BDS



1

ESTHETIC POST SYSTEMS



HISTORICAL PERSPECTIVE

For over 250 years, clinicians have written about the placement of posts in the roots of teeth to retain restorations.^{1,2}

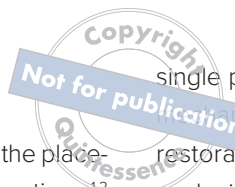As early as 1728, Pierre Fauchard described the use of “tenons,” or metal posts screwed into the roots of teeth to retain bridges.^{1,3–6} In the mid 1800s, wood replaced metal as the post material, and the “pivot crown” became popular among dentists; this was a wooden post fitted to an artificial crown and the canal of the root.^{1,2,7} Often these wooden posts would absorb fluids and expand, frequently causing root fractures.^{4,7} In the late 19th century, the “Richmond crown,” a single-piece post-retained crown with a porcelain facing, was engineered to function as a bridge retainer.^{2,7} During the 1930s, the custom-cast post and core was developed to replace the one-piece post crowns. This procedure required casting a post and core as a separate component from the crown.⁷ This two-step technique improved marginal adaptation, allowed variation in the path of insertion of the crown,¹ and provided a better alignment of the core when the tooth being restored was flared or overlapped the adjacent tooth. In the 1990s, tooth-colored fiber posts debuted as an alternative to these conventional metal post systems.^{8–17}

From the past to the present, the rationale for the utilization of a post system has metamorphosed. The concepts of the past were designed with the belief that endodontically treated teeth (ETT) were brittle from a loss of moisture^{18,19} and required a post to strengthen the weakened tooth.^{20–26} Although there is a reduction in moisture content after endodontic treatment, current concepts refute this postulate.^{18,19,27–36} Current concepts supported by evidence-based research indicate that the primary objective of any post and core system is to replace missing coronal tooth structure, to retain the core,^{37–44} and to provide sufficient retention^{41,43,45–54} and resistance form to the final restoration to restore original form and function.^{37–39,55–69} Today, clinicians can choose from a variety of user-friendly post and core systems^{29,70–81} for different endodontic, restorative, and esthetic requirements. These systems and methods are well documented in the literature.^{23–25,29,40,42,80–99} However, no

single post system meets the demands for favorable biocompatibility^{65,80,100–102} or provides the perfect restorative solution for every clinical circumstance, and each situation requires an individual evaluation.⁸²

Furthermore, the reconstruction of ETT can present restorative and esthetic challenges for the technician and the clinician.^{9,80,103–105} The failure of these post-retained systems has been documented in numerous clinical studies.^{22,39,45,51,66–68,101,106–150} Many of these studies indicate that the failure rate of restorations on pulpless teeth with posts and cores is higher than that for restorations of vital teeth^{106,151–163} because of their structural differences and the significant loss of tissue.³⁶ Several main causes of failure of post-retained restorations have been identified, including recurrent caries,^{164,165} endodontic failure,¹⁶⁵ periodontal disease,¹⁶⁵ post dislodgment,¹⁶⁵ cement failure,¹⁶⁶ post-core separation,¹⁶⁵ crown-core separation,¹⁶⁵ loss of post retention,^{40,164} core fracture,¹⁵² loss of crown retention,^{40,164} post distortion,¹⁶⁴ post fracture,^{40,152,164,166} tooth fracture,^{152,166} root perforation,⁴⁰ and root fracture.^{40,152,164,167,168} Also, corrosion of metal posts has been proposed as a cause of root fracture.¹⁵² A post and core system fabricated with dissimilar metals can cause galvanic corrosion that occurs between the two dissimilar materials.^{19,169} This gradual destructive process involves the electrical interaction of at least two different metals or nonmetallic conductors in an environment (ie, microleakage) that accelerates the corrosion of at least one of them, while the least noble metal corrodes the most (for more information, see the section entitled “Lack of corrosiveness” later in this chapter).

The traditional custom-cast dowel core provides a better geometric adaptation to excessively flared or elliptical canals and almost always requires minimal removal of tooth structure.¹ Custom-cast posts and cores adapt well to extremely tapered canals or those with a noncircular cross section and/or irregular shape and roots with minimal remaining coronal tooth structure.^{82,89} Patterns for custom-cast posts can be formed either directly in the mouth or indirectly in the laboratory. Regardless, this method requires two appointment visits and a laboratory fee. Also, because it is cast in an alloy with a modulus of elasticity that can be as



high as 10 times greater than that of natural dentin,⁵⁵ this possible incompatibility and rigidity can create stress concentrations in the less rigid root, resulting in post separation or failure.^{170–172} Additionally, the transmission of occlusal forces through the metal core can focus stresses at specific regions of the root, causing root fracture⁵⁵ (Fig 1-1). Furthermore, upon esthetic consideration, the cast-metal post can result in discoloration and shadowing of the gingiva and the cervical aspect of the tooth¹⁷³ (Fig 1-2).

An alternative and currently more popular method is the prefabricated post and core system. Prefabricated post and core systems are classified according to their geometry (ie, shape and surface configuration) and method of retention. The methods of retention are designated as active or passive. Active posts engage the dentinal walls of the post space preparation during cementation, whereas passive posts do not engage the dentin but rely on cement for retention.^{1,174} The basic post shapes and surface configurations are tapered serrated, tapered smooth-sided, tapered threaded, parallel serrated, parallel smooth-sided, and parallel threaded. While active or threaded posts are more retentive^{175–178} than passive posts, active posts create high stress concentrations in root dentin at each thread during placement.^{177,179–184} These stresses have the potential to create cracks^{185,186} that can increase the susceptibility of root fracture^{127,184} when occlusal forces are applied.¹⁰ Thus, a significant cause of failure with an active post system is root fracture.^{52,184,187,188} More recent modern designs provide a collar that limits insertion, flexible tips (FlexiPost), and stress-reducing thread design. Metal screws have a survival rate of 78%^{127,184} after 1 year and 50% after 5 years.¹⁸⁴

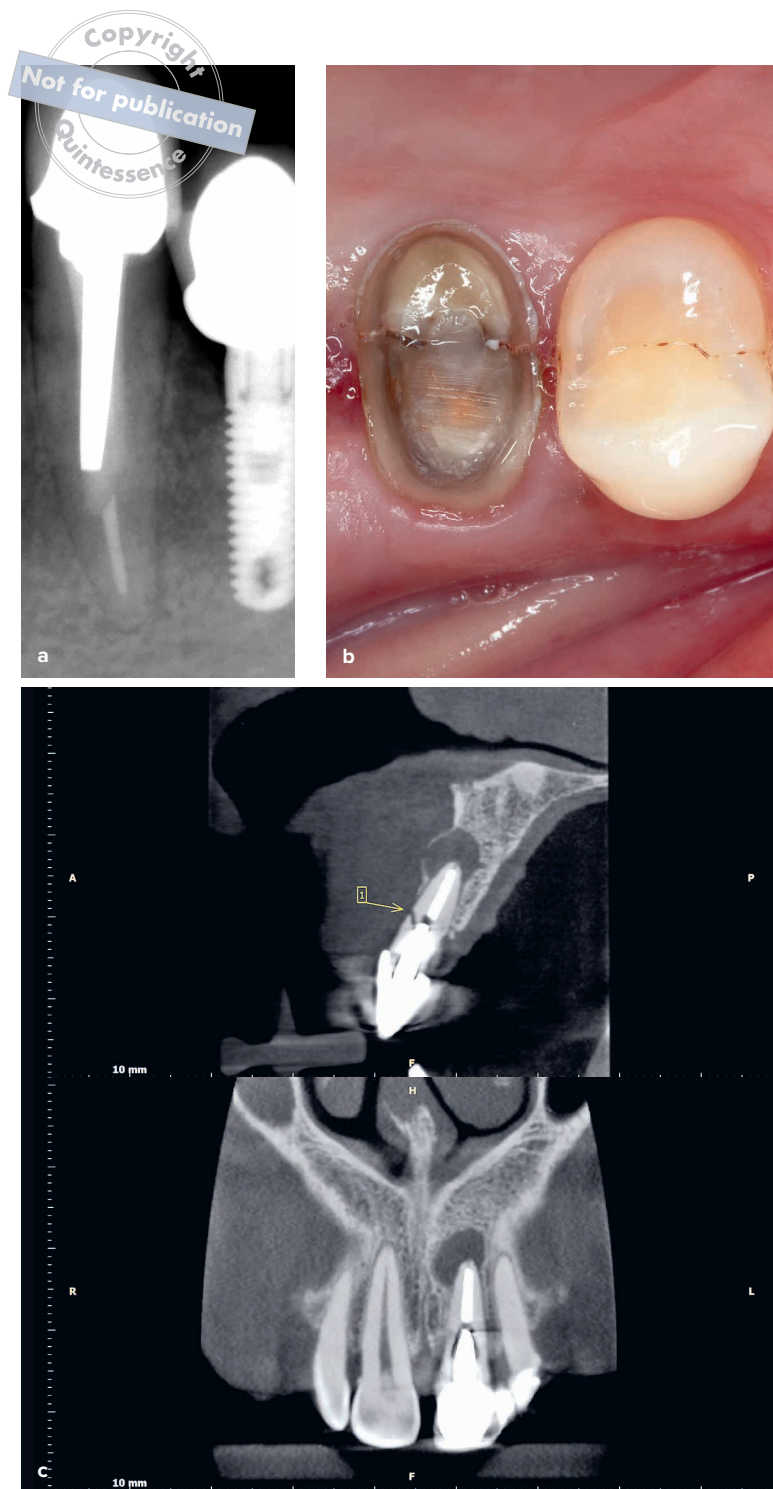


Fig 1-1 (a) Occlusal forces are transmitted through the metal post in the mandibular right canine, and stress concentrations are focused in the mesial aspect of the apical one-third of the root, resulting in a horizontal fracture. (b) A vertical fracture occurs in the maxillary right second premolar with a metal post present. (c) A CBCT shows a horizontal fracture in the maxillary left central incisor. (Radiograph courtesy of Ritu Sharma, BDS, MDS.)

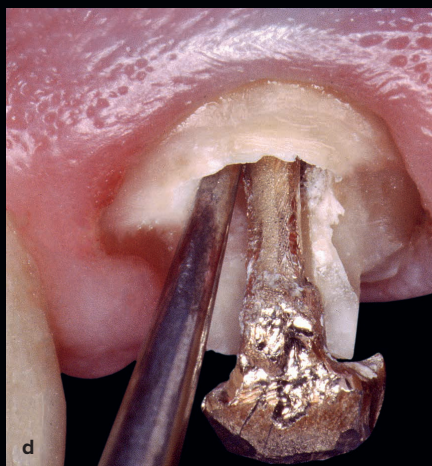
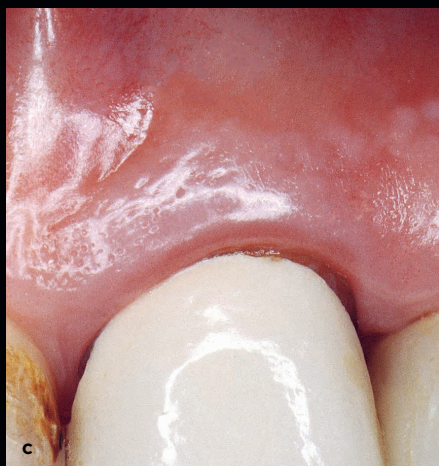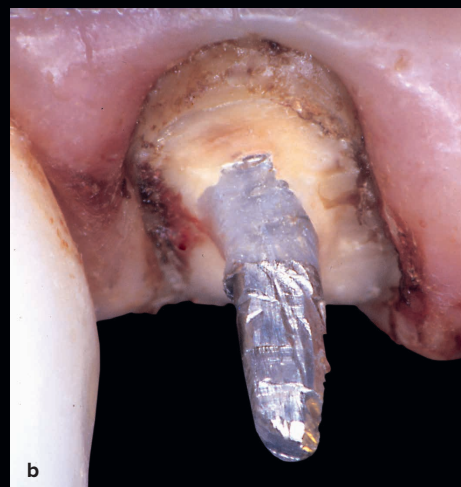

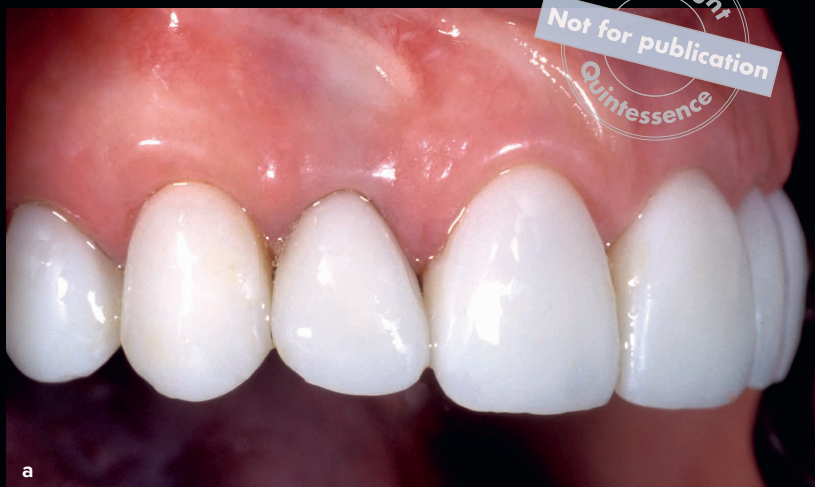
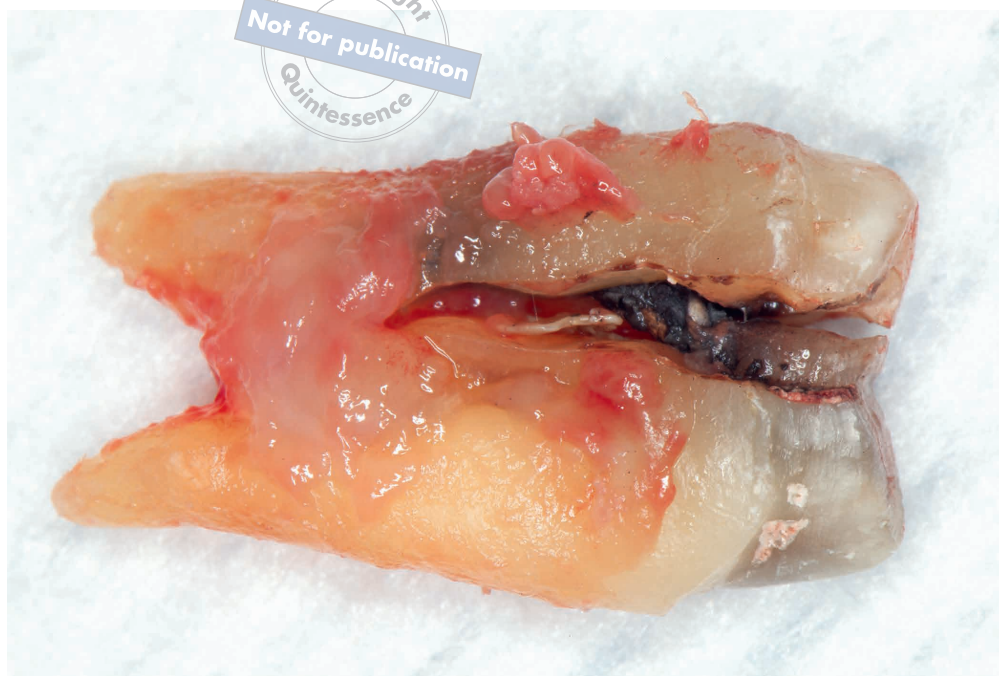Fig 1-2 (a and b) A maxillary right lateral incisor is restored with a cast-metal post. This can result in discoloration and shadowing of the gingiva and the cervical aspect of the tooth. (c to e) The incidental light is completely blocked by the metal post and the underlying metal framework of the crown, which causes the characteristic shadow at the submarginal zone.



Fig 1-3 Posts and cores fabricated from materials with a high modulus of elasticity and a combination of noble and non-noble alloys in the oral environment may result in electrochemical reactions such as corrosion of metals, which can cause root fracture.



Parallel-sided serrated posts are the most retentive of the passive prefabricated posts, and the tapered smooth-sided posts are the least retentive of all designs.⁷

Traditional prefabricated metal posts are made of platinum-gold-palladium, brass, nickel-chromium (stainless steel), pure titanium, titanium alloys, and chromium alloys.^{7,37–39,164} Although stainless steel is stronger, the potential for adverse tissue responses to the nickel has resulted in the use of a biocompatible titanium alloy.^{189,190} Also, contributing factors to root fracture such as excessive stiffness (modulus of elasticity)^{191–193} and post corrosion^{7,121} (Fig 1-3) from many of these metal posts have generated concerns about their use. In addition, prefabricated metal posts can negatively affect the esthetic result.

Nonmetallic prefabricated posts have been developed as alternatives,¹⁹⁴ including ceramic (white zirconia) posts, carbon-fiber posts, and fiber-reinforced resin posts. Zirconia posts have a high flexural strength and are biocompatible as well as corrosion resistant.¹⁹⁵ This material, however, is difficult to section intraorally with a diamond bur and difficult

to remove from the canal for retreatment.¹⁶⁴ Carbon-fiber posts are made from unidirectional carbon fibers held together with an epoxy resin and ceramic. They exhibit strength and relatively high flexibility and can be retrieved from the canal preparation with ease for retreatment. However, their black color has a negative effect on the final esthetic result of all-ceramic crowns.¹⁸⁹ New advances with next-generation tooth-colored posts, which are identical in design to conventional carbon-fiber posts, reduce this esthetic challenge. There are several methods for the fabrication of the direct fiber-reinforced resin system that include a bondable polyethylene woven reinforcement fiber (Ribbond-THM, Ribbond; Construct, Kerr/Sybron), a prefabricated fiber-reinforced composite post system, a direct anatomical formed fiber-reinforced composite post system,^{105,195,196} a direct/indirect anatomical formed fiber-reinforced composite post system, and an indirect anatomical formed fiber-reinforced composite post system (see the section entitled “Direct Fiber-Reinforced Post and Core System” later in this chapter).

CONSIDERATIONS FOR THE SELECTION OF RESTORATIVE MATERIALS



Maximum post retention and core

As the clinician continues the search for optimal functional and esthetic success with a post-retained crown system, the current selection of restorative materials and techniques may prove overwhelming. While no single system provides the ideal restorative solution for every clinical circumstance, understanding both general design criteria and the components for the various post and core systems available allows the clinician to appropriately select the method and materials compatible with the existing tooth structure and desired result. A *system* is defined as any set of components working together for the overall objective of the whole.¹ Selecting the proper post and core system for a specific clinical situation requires an evaluation of the various components and interfaces of the system.^{197,198} The components of the direct fiber-reinforced composite resin post system are the surface of the root dentin, the intraradicular post, the core buildup, the luting cement, and the final restoration¹⁹⁹ (Fig 1-4). The system can be analyzed in four regions: (1) at the intraradicular surface (dentin surface), (2) at the post-tooth interface, (3) within the core, and (4) intracoronally. For the successful rehabilitation of the ETT, it is imperative to understand the disparity and complexity of the interrelationship of these interfaces with various restorative materials.⁵⁵ The failures of each system provide us with design principles that can be utilized with any post-retained crown system. These specific design principles bring us to higher levels of understanding potential problem areas in any restorative situation. Therefore, the following design principles should be considered when using any post-retained crown system. An evaluation of the direct fiber-reinforced resin post system with these design principles is provided.

Dislodgment and tooth fracture are causes for failure of post and core restorations. The majority of clinical failures involving fiber-reinforced post systems occur through debonding.^{15,29,45,80,100,119,120,124–126,200–215} Core stability and post retention are important in preventing these failures in the restoration of ETT^{51,105,164,166,168,177,193,216–218} (Fig 1-5). The ideal post system should replace lost tooth structure while providing adequate retention and resistance for the core and final restoration while transferring occlusal forces during function and parafunction to prevent root fracture. Adhesive post systems allow conservative minimally invasive preparations that preserve sound tooth structure and strengthen the remaining tooth. However, meticulous adhesive protocols are required for reliable bonding and effective adhesion. Improving the quality of the adhesive interface and the long-term adhesion of fiber-reinforced post systems to dentin requires improving resin impregnation into dentin,^{212,219–227} enhancing the strength of the polymer formed by the adhesive system,^{212,228–252} and increasing the resistance of collagen fibrils to enzymatic degradation.^{212,253–273} Because the root canal anatomy can impose limitations to achieving a quality hybrid layer, modified clinical protocols have been suggested. Studies indicate that various methods and materials can improve the stability of the resin-dentin bond.

Numerous studies suggest methods and materials to improve resin impregnation into dentin. One study indicates that diamond bur preparation of the post channel in comparison to a carbide bur allows the etching procedure to remove the smear layer more efficiently with more open dentinal tubules and with fewer smear layer remnants. Thus, the acid-resistant smear layer produced by the manufacturer's carbide bur for post space preparation can be removed with a similar-diameter diamond bur, and the replaced smear layer will be more susceptible to phosphoric acid dissolution.^{212,220} Other studies indicate that liquid phosphoric acid applied with an endodontic needle improved the removal of the smear layer better than

Fig 1-4 The five components of the post-retained crown system are the internal root dentin surface, luting cement, intraradicular post, core buildup, and the crown. The system can be analyzed at each of the four interfaces: at the dentin surface, at the post-tooth interface, within the core, and intracoronally.

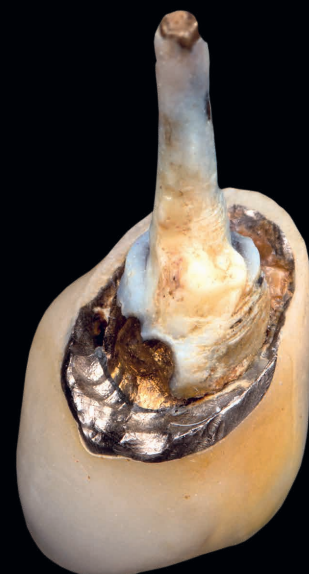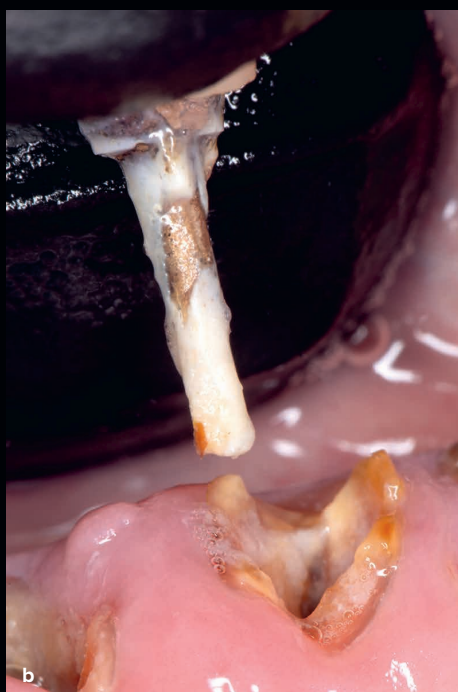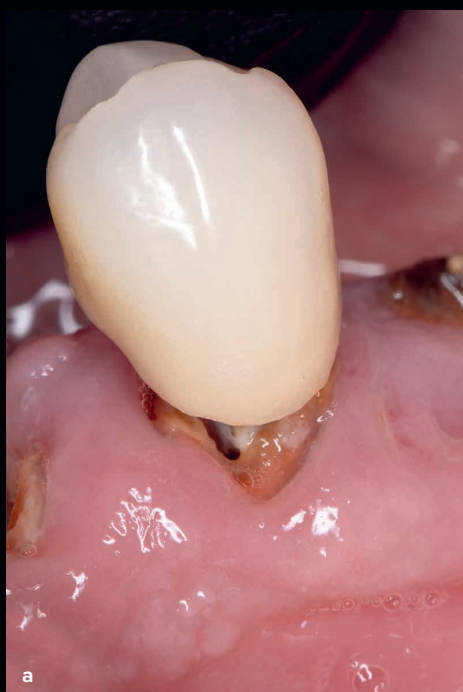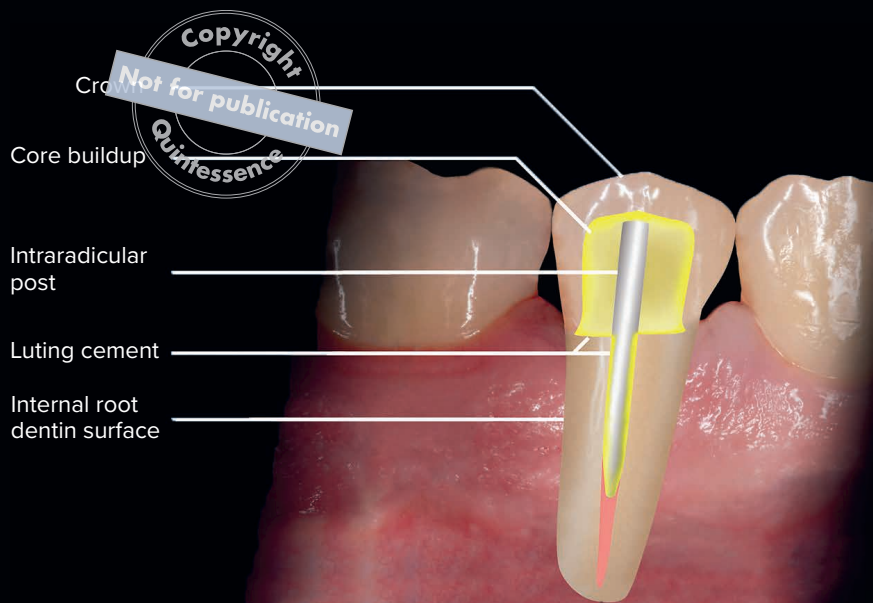


Fig 1-5 (a to c) Failure of a post-retained system. The metal-ceramic crown with gold post dislodges from the intraradicular space as a result of microleakage and recurrent caries at the interface.

gel etchants and that higher bond strengths to the dentin were achieved when an etch-and-rinse adhesive system was utilized.^{212,226,227} Several studies indicate that vigorous rubbing of the adhesive may improve the permeability of the etchant into the dentin collagen network.^{223,224} Other studies indicate that the application of multiple layers of simplified etch-and-rinse adhesives and self-etch adhesives to coronal dentin yield higher immediate bond strengths.^{221,222} However, this modified protocol should be applied with caution to prevent post seating because of the increase in thickness of the hybrid layer. It is suggested that paper points or a vacuum capillary tip adapter (Luer Vacuum Adapter, Ultradent) can be utilized to absorb the excess solvent.²¹²

Various studies suggest methods and materials to enhance the strength of the polymer formed by the adhesive system. Studies indicate that the use of a hydrophobic coating after the application of a simplified self-etch adhesive and an etch-and-rinse adhesive system provides a thicker and more uniform adhesive layer with lower concentrations of water and solvent and thus a significant reduction in fluid flow rate.^{235,240} This procedure transforms a simple-layer adhesive into a multilayer adhesive. This method ensures that the hydrophilic layer is photoactivated prior to the application of the hydrophobic, non-solvated bonding resin. This allows for the simplified adhesive layer to be more concentrated with hydrophobic monomers from the additional coating.^{212,232,241} Thus, by reducing the concentration of unreacted monomers between the primed and bonded layers, a more compacted and stable resin-dentin interface can be achieved.^{212,235} However, this modified protocol should be applied with caution to prevent a thick adhesive layer that could interfere with post seating.²¹² Numerous studies suggest that the application of ethanol to replace water in acid-etched collagen will allow hydrophobic resins to infiltrate the demineralized dentin and create a hydrophobic hybrid layer.^{231,239,242,252} Because endogenous matrix metalloproteinases (MMPs) become inactive in the absence of water, one study suggests that the application of ethanol is a potential mechanism for increasing the longevity^{212,250} and durability^{274–276} of resin-dentin bonds. However, several

authors indicate that ethanol wet bonding yielded higher bond strengths and resulted in lower nanoleakage in root canals.^{237,246} Although there are differences in the suggested protocol in regard to concentration and time of application, a recent study suggested a simple higher concentration (50%) of ethanol for 60 seconds.²⁶⁶ Others indicate that using a high-intensity light-curing unit and/or increasing the irradiation time for the adhesive systems and resin cements will improve the adhesion of these systems to the canal wall dentin.^{228,230,244,249} One paper indicated that increasing the light-curing time improved bond strengths to root dentin.²²⁹

A myriad of studies suggests methods and materials for increasing the longevity of hybridization by improving the resistance of collagen fibrils to enzymatic degradation.^{207,277,278} Several studies suggest the application of chlorhexidine (CHX) as a protease inhibitor for MMPs²⁶¹ and cysteine cathepsins²⁷⁰ to preserve the hybrid layer from degradation. Furthermore, several studies indicate that a 2% CHX or a CHX-containing phosphoric acid for etch-and-rinse adhesive systems may be an excellent method for increasing the long-term stability of collagen fibrils in the hybrid layer by inhibiting endogenous MMPs and cathepsins.^{268,269}

It has been demonstrated that the use of ethylenediaminetetraacetic acid (EDTA) inhibits MMP-2 and MMP-9 when applied for 1 to 5 minutes,^{260,272} while one in vitro study indicated an application of EDTA preserved the dentin-adhesive interface.²⁶⁶ Thus, the use of EDTA has been indicated as a dentin pretreatment for dentin adhesives.^{212,266} However, one study demonstrated that prolonged rinsing with water removes the EDTA and there may be no residual EDTA to inhibit the degradation by endogenous MMPs.²⁶⁰ Several studies indicate that an increase in the extent of cross-linking of the collagen fibrils prior to adhesive application may increase the potential for durability, while other studies indicate that cross-linkers enhance the mechanical properties of these substrates. Cross-linking agents have been purported to have anti-MMP properties,^{253,257} thus reducing enzymatic degradation.²⁷³ However, the application time for desirable therapeutic effect is not feasible,^{279,280}

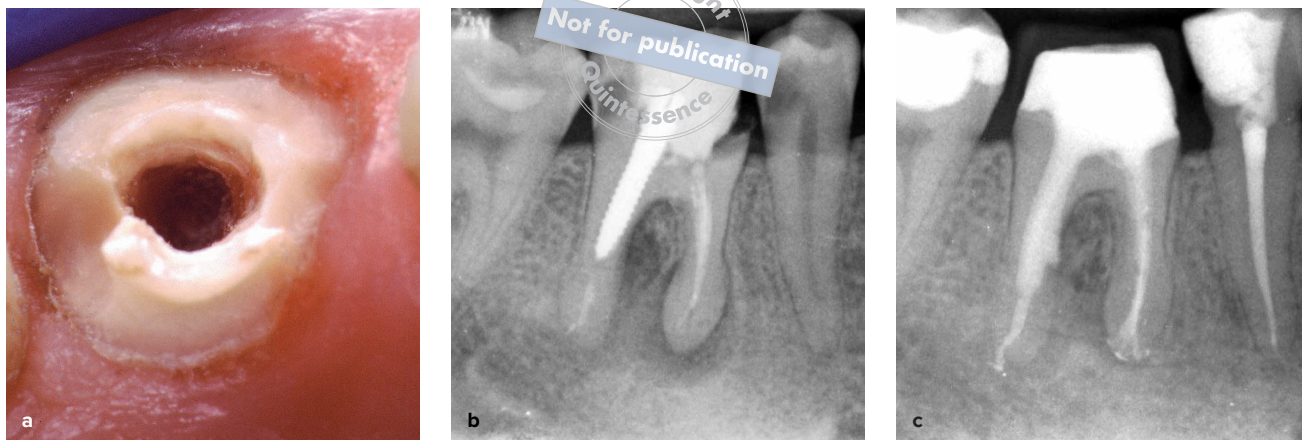


Fig 1-6 (a) Overpreparation of the post space to accommodate a larger selected fiber-reinforced post can weaken the remaining tooth structure and increase the potential for root fracture. (b) Root perforation caused by improper preparation and placement of an oversized post. (c) Repair of the perforation seen in b. (Dentistry in b and c courtesy of Riccardo Tonini, MD, DDS)

and modification into a simplified protocol using proanthocyanidins incorporated into etchants and adhesives is recommended.^{254,256,258,259} Several studies indicate the use of benzalkonium chloride (BAC) or BAC-containing acid or adhesives to inhibit the activity of the endogenous MMPs.^{264,271} Because the root canal anatomy can impose limitations to achieving a quality hybrid layer, modified clinical protocols may have positive implications for improving the quality of the adhesive interface and the long-term adhesion of fiber-reinforced post systems to dentin. This in turn can improve the structural integrity of the remaining radicular dentin and increase the retention and resistance to displacement^{55,168,281} while dissipating and reducing functional stresses along the entire adhesive interface, thus providing maximum post retention and core stability.















Conservation of tooth structure

Numerous in vitro studies support evidence that conservation of sound tooth structure is the most important factor to the successful management of structurally compromised ETT.^{47,51,216,282–288} It is well supported in the literature that the longevity of an ETT is directly related to the amount of remaining sound tooth structure.^{29,43,289} However,

traditional-cast post systems and prefabricated post systems often require the removal of undercuts for a proper path of insertion and adaptation to the canal wall. This enlargement of the post-endodontic channel throughout biomechanical preparation during and after the endodontic procedure removes dentin during cleaning and shaping of the canal. The removal of additional dentin to accommodate placement of a larger post diameter significantly weakens the remaining tooth structure^{175,285,290} (Fig 1-6). This widening of the canal decreases the thickness of the root wall, which can lead to a diminished wall stiffness that results in increased stress levels^{291,292} and can compromise long-term success.^{293,294} It is widely accepted that 1 mm of dentin wall thickness is required to prevent root fracture and to properly support the core.^{159,295}

Additionally, during post channel preparation, the preservation of 4 to 5 mm of gutta-percha is necessary to provide an adequate apical seal.^{201,296–307} Several techniques for preparing the post channel and the effect of each technique on the apical seal have been investigated and include the use of rotary instruments, heated instruments, and solvents.^{175,299,304,308–310} An improper access preparation with too wide an enlargement when performing endodontic therapy can result in an excessive loss of sound coronal

Table 1-1 General guidelines for post placement³

Tooth type	Number of roots/ canals	Anatomical root canal variations ³	Cervical cross section	Preferred root canal for post channel placement	Cervical cross- sectional shape of the preferred canal
Central incisor					
Maxillary	One root, one canal	99.4%		Main single canal	Circular, ovoid
Mandibular	One root, one canal One root, two canals	73.6% 26% incidence of second canal usually lingual to the main canal		Main single canal	Ovoid, ribbon-shaped
Lateral incisor					
Maxillary	One root, one canal	93.4%		Main single canal	Circular, oval, or ovoid
Mandibular	One root, one canal One root, two canals	71.8% broad buccolingually and narrow mesiodistally 28.1% incidence of second canal usually lingual to the main canal		Main single canal	Ovoid, ribbon-shaped
Canines					
Maxillary	One root, one canal	96.5%		Main single canal	Oval
Mandibular	One root, one canal	94.8%, 89.4% (10.6% incidence of second canal usually lingual to the main canal)		Main single canal	Ovoid
First premolars					
Maxillary	One root, one canal Two roots, two canals Three roots, three canals	52.2%, 21.3% 46.7%, 75.8%; mesial developmental root depression; root concavities are present on both mesial and distal surfaces of the root 1.15%, 1.4%		Main single canal Palatal root	Round, ovoid
Mandibular	One root, one canal	97.9%, 72.2%		Main single canal	Ovoid
Second premolars					
Maxillary	One root, one canal	90.7%, 50.3%; developmental depressions are often present on the mesial and distal aspects of the root		Main single canal	Ribbon-shaped, elliptical
Mandibular	One root, one canal	99.6%, 91.1% (8.9% incidence of second canal)		Main single canal	Ovoid
First molars					
Maxillary	Three roots, three canals	95.9%; mesiobuccal 42.9%; two mesio- buccal canals 57.1%; distobuccal 98.3% (only variation in mesiobuccal canal)		Palatal root	Circular, ovoid
Mandibular	Two roots, three canals	85.2%; two mesial canals (100%); distal root one canal (68.3%)		Distal root	Ovoid
Second molars					
Maxillary	Three roots, three canals	88.6%; mesiobuccal 52.9%; distobuccal (99.7%); palatal (99.9%)		Palatal root	Circular, ovoid
Mandibular	Two roots, three canals One root	76.2%; two mesial canals (86%); one distal (85.1%) C-shaped (8.5%) and single conical roots (8.3%)		Distal root Main single canal	Elliptical, C-shaped C-shaped

This table indicates anatomical root canal variations in Asian and non-Asian populations. However, anatomical variations exist in different subpopulation groups. The table provides the necessary information for post preparation and placement. During post channel preparation, the preservation of 4 to 5 mm of gutta-percha is necessary to provide an adequate apical seal.^{201,296-307}

*If there are two numbers, the first number is the prevalence for that number of roots for a given tooth, and the second number is the prevalence for that number of canals for said tooth among the population groups studied.

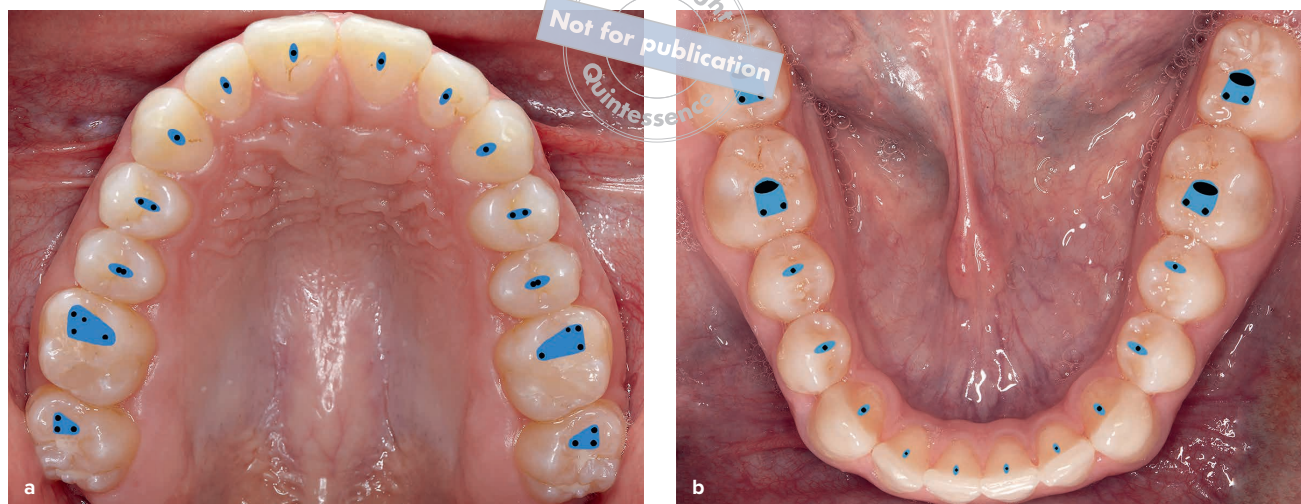


Fig 1-7 (a and b) Conservative endodontic access openings.

tooth structure^{20,40,311,312} and increase the occurrence of fractures^{43,206,291,313} (Fig 1-7). In addition, endodontic access on a tooth with loss of one or both marginal ridges increases the potential for fracture.^{29,44,314–317} Investigators have reported that rotary instruments caused more dentinal defects, such as craze lines and partial cracks, which have the potential to develop into fractures after endodontic and restorative treatment.^{318–320} However, no defects were observed with hand file instrumentation.³¹⁸ Furthermore, overpreparation of the post space and the utilization of larger posts decrease the resistance to fracture.^{51,285,287} This reduction in the amount of dentin weakens the structural integrity of the tooth²¹⁶ and can be responsible for horizontal and vertical root fracture.^{291,321–326} To prevent overpreparation during the endodontic or restorative procedure, it is recommended that the root morphology be considered for each tooth type prior to treatment. Mandibular incisors, maxillary second premolars, and the distal root of mandibular molars have mesiodistal concavities and may be narrower mesiodistally than they appear in the radiograph.³²⁷ A CBCT image can provide a 3D visualization of these anatomical features in cross section and reduce the potential for a weakened

structural integrity or root perforations³²⁸ by providing a view of the tooth anatomy. Because of the wide range in anatomical variation in regard to number and shape of roots and root canals for each tooth type,^{329–335} a comprehensive knowledge of root morphology^{179,336} and an understanding of external root anatomy can provide insight for selecting the teeth and roots that are most appropriate for post placement with less potential for thinning and root fracture³⁰⁰ (Table 1-1; for further information, see section entitled “Guidelines for Restoring the Intraradicular Space”^{300,337–339}).

Improvements in composite materials, adhesive technology, and endodontic procedures and technology have resulted in a more conservative design concept.⁹ This minimally invasive concept preserves intact tooth structure, reducing the potential for failure²⁰⁹ while providing adequate retention and resistance form for the final restoration.⁴⁰

One method of the direct fiber-reinforced resin post system (see section entitled “Direct Fiber-Reinforced Post and Core System”) allows preservation of the canal structure and can be utilized in the treatment of irregular canal configurations. This procedure does not require a converging path of insertion and can be used with minimal preparation

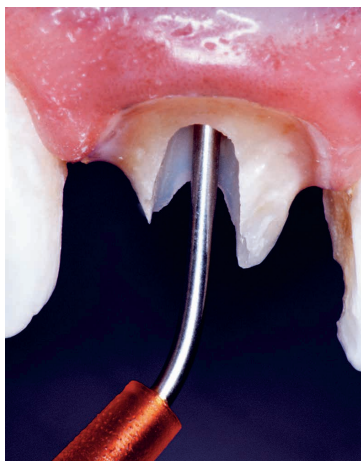

Fig 1-8 A dual-cured composite or resin cement was injected into the post channel with a needle-tube syringe. It is important to place the tip to the base of the channel and inject slowly while removing the tip slowly.

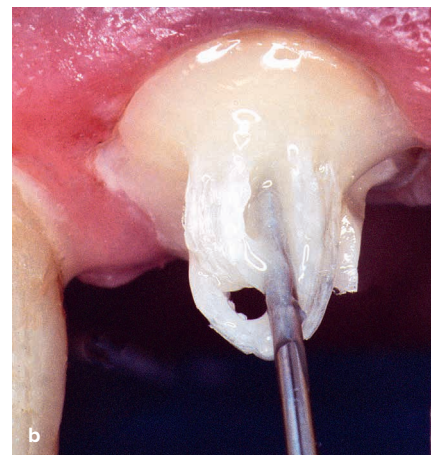
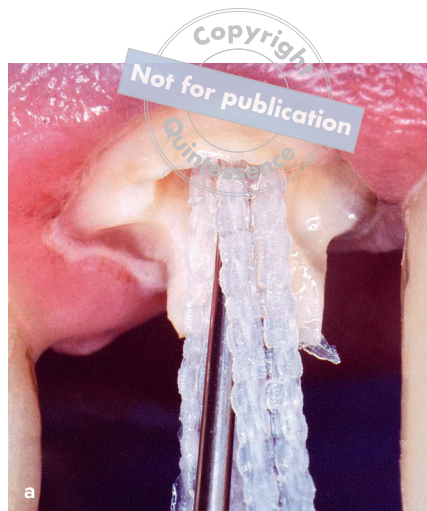

Fig 1-9 (a and b) The intraoral fabrication of a direct fiber-reinforced post using a plasma-coated fiber ribbon. After the adhesive protocol and injection of a dual-cured resin cement, the fiber is immediately inserted into the posthole with a modified Luk's gutta-percha condenser, and the fiber is folded over so that the ends are pointing back into the post channel and between the emerging ends of the fiber. This method allows preservation of the canal structure and can be utilized in the treatment of irregular canal configurations.

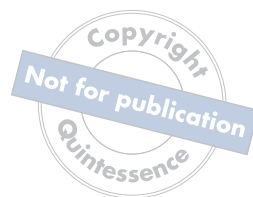because it utilizes the undercuts and surface irregularities to increase the surface area for bonding (see Fig 1-9). This conservation of dentin reduces the possibility of tooth fracture during function or in the event of traumatic injury.²⁸⁷

Internal adaptation

Conventional luting cements such as zinc phosphate only fill the void between the restorative interfaces without attaching to either surface.⁵⁵ Dual-cured resin luting agents mechanically and chemically interact with the resin of fiber-reinforced composite resin posts and the dentin, which bonds and seals the adhesive interface. Previous methods of cementation have been investigated that include placement of the cement onto the post and/or placing the cement with paper points, an endodontic explorer, and lentulo spiral.^{175,340,341} The lentulo spiral was considered the superior method of placement, providing a uniform thickness of cement with no voids.³⁴¹ The author prefers placement of the adhesive resin cement onto the post and injection of the material with a needle tube placed at

the base of the prepared post space, slowly removing the syringe tip to prevent the formation of air voids¹⁹⁶ (Fig 1-8). The use of composite resin cements between the adhesive system and the reinforcement material ensures a more intimate contact with the dentin bonding agent because of lower viscosity that results in enhanced adaptation.³⁴² One study claims that low-elastic modulus composite acts as an elastic buffer that compensates for polymerization shrinkage stress by flow, minimizing gap formation and reducing microleakage³⁴³; however, there is no evidence that flowable-lined composite restorations have improved margins or reduced leakage. If the elastic modulus is low, the composite will flex as the tooth bends, thus minimizing fracture. Also, lower-viscosity resin cements enhance post and dentin wetting, improving the interfacial internal adaptation and reducing void formations that contribute to reduced post retention and increased microleakage.³⁴⁴ Therefore, the use of a resin luting cement to line and strengthen the canal walls actually reinforces the root and supports the tooth-restorative complex^{166,345} (Fig 1-9).

INDEX



Page references followed by “f” denote figures; those followed by “t” denote tables.

A

Access openings, sealing of
 case study of, 177–180, 177f–180f
 with composite layering technique in
 ceramic crowns, 181–183, 181f–183f

Acid etching
 adhesives for, 76
 of enamel, 72–73
 smear layer removal with, 75

Acid-resistant smear layer, 6

Actinobacillus actinomycetemcomitans, 177

Active posts, 3

Adherend, 70

Adhesion
 in adsorption, 70
 criteria for improving, 98
 definition of, 64, 70
 eugenol effects on, 69
 mechanisms of, 72, 72f, 85–86
 polymerization shrinkage versus, 78–79
 at restorative interface, 70–72, 98–99
 specific energy of, 70

Adhesive(s)
 acid-etching, 76
 characteristics of, 70
 etch-and-rinse. *See* Etch-and-rinse
 adhesives.
 fillers in, 77
 interfaces, 70, 98
 multimode universal, 77
 self-etching, 76
 universal, 77, 132, 143, 179f, 183
 viscosity of, 70

Adhesive bonding agent, 23

Adhesive cements
 composite resin cement, 82–83
 glass-ionomer cements, 82

Adhesive design concept
 case studies of, 99–111, 100f–110f
 cavity preparation, 87–88
 clinical technique for, 88–98
 elements involved in, 63f
 overview of, 62–64

post-retained system and, integration
 of components between, 196–198,
 196f–198f
 schematic diagram of, 63f

Adhesive post systems
 description of, 6
 polymer strength, 8
 principles for, 26b
 summary of, 42

Adhesive resin cements
 cavity preparation design for, 87–88
 concerns about, 85
 description of, 83–85
 dual-cured, 83
 self-adhesive, 84–85
 self-cured, 83

Adhesive restorations
 adhesion interface with, 70–72, 98–99
 placement procedures and techniques for,
 97–98

Adsorption, 70

All-ceramic crown
 acid etching of, 181
 adhesive cementation of, 225
 case study of, 192f
 dislodgment of, 142

All-ceramic fixed partial denture, 162, 163f

Anisotropic fiber-reinforced post systems, 17,
 80–81

Anterior teeth
 biomechanical properties of, 15
 direct fiber-reinforced post system in,
 167–169, 167f–169f
 prefabricated fiber-reinforced post system
 in, 130–133, 130f–133f

Apatite, enamel, 66

Apical seal, 41

Aprismatic enamel, 73f

B

Benzalkonium chloride, 9

Biologic width
 crown lengthening for, 35f
 description of, 29–30, 30f
 orthodontic extrusion for, 38f

Biomaterials. *See also* Restorative materials.
 selection of, 79
 tooth preparation design based on, 86–87

Biopsy punch, 227

Biphenyl dimethacrylate, 75

Bleaching, 130

“Blue-light hazard,” 94–95

Bondable reinforcement fiber, 20, 22

Bonded restorative complex, 70

Bonding, 64

Bonding materials, 64

Bone allograft, 222, 234, 243

Bone grafting, 216

Bone regeneration, 216, 217f

Bovine bone graft, 226

Buccal bony dehiscence, 234

Buccal flap, 157

C

CAD/CAM technology, 199

Camphorquinone photoinitiator, 90

Carbide burs, 6, 74f

Carbon-fiber posts, 5

Cast-metal post
 discoloration caused by, 3, 4f
 light-transmission properties of, 13

CEJ. *See* Cementoenamel junction.

Cement
 adhesive. *See* Adhesive cements.
 adhesive resin. *See* Adhesive resin
 cements.
 luting. *See* Luting cements.
 universal, 86

Cementation
 of all-ceramic crowns, 225
 challenges associated with, 86

Cementoenamel junction, 216

Centrix syringe tip, 140

Ceramic bridge, 187

Ceramic endocrowns, 199

Ceramic posts
 characteristics of, 5
 fiber-reinforced composite posts versus, 15

Ceramics

- crowns, endodontic access openings
 - sealed using composite layering technique in, 181–183, 181f–183f
 - surface treatment of, 86
- Cervical deficiency, 211
- C-factor. *See* Configuration factor.
- Chlorhexidine, 8, 160
- Cohesion, 70
- Collagen fibrils, enzymatic degradation of, 8
- Composite(s)
 - core buildup uses of, 42, 81
 - fiber-reinforced. *See* Fiber-reinforced composites.
 - layering technique, for endodontic access opening sealing in ceramic crowns, 181–183, 181f–183f
- Composite post and core systems
 - characteristics of, 25
 - prefabricated, 19
- Composite resin cement, 82–83
- Compressive stresses, 15
- Compromised tooth, 129
- Configuration factor, 23, 87
- Connective tissue graft, 158, 212, 235, 245
- Contact angle, 70
- Core buildup, 25–26, 81, 153
- Corrosion
 - expansion stresses caused by, 16
 - of metal posts, 2
 - restorative material resistance to, 16
- Cross-linking agents, 8
- Crown lengthening
 - ferrule effect created by, 30, 32f–33f, 33
 - indications for, 33
 - mandibular, 36f
 - orthodontic extrusion versus, 39
 - surgical procedure for, 33f–35f
- Curing contraction, 79
- Custom-cast posts and cores, 2
- Cyanoacrylate, 148

D

- DEJ. *See* Dentinoenamel junction.
- Delayed implant placement
 - mandibular molar restoration with, 226–232, 226f–232f
 - maxillary premolar restoration with, 233–240, 233f–240f
 - single posterior implant, 220–225, 220f–225f
- Dental dam, 97, 130, 154
- Dentin
 - adhesive surface preparation of, 62
 - characteristics of, 67–69
 - cytoplasmic extensions in, 68f
 - density of, 68
 - enamel and, comparison between, 66–68

hybrid layer, 67–72f

- hybridization, 67–72f
- hydroxyapatites of, 67
- intertubular, 67–68, 68f, 71f
- matrices in, 68
- microstructure of, 67
- modulus of elasticity of, 17
- periodontoblastic matrix of, 68
- peritubular, 67–68, 68f
- removal of, 9, 66
- resin impregnation into, 6
- resin-modified cement bonding to, 82
- restorative material and, interface
 - between, 67
- selective demineralization of, 76
- smear layer of, 73–74, 74f
- structure of, 67, 68f
- surface area of, 67
- Dentin bonding systems, 75
- Dentinal fluid, 68
- Dentinal tubules
 - description of, 67–68
 - smear layer occlusion of, 74
- Dentinoenamel junction
 - characteristics of, 69–70
 - dentinal tubules at, 67
 - description of, 65
 - imaging of, 69f
- Dentinoenamel junctional complex, 69
- Diagnostic wax-up, 212
- Diamond burs
 - gingival margin preparation using, 146
 - post channel preparation using, 6, 41, 113
 - surface treatment uses of, 74f
- Diffusion, 70
- Direct fiber-reinforced composite resin post system
 - advantages of, 17
 - components of, 6
 - method of, 11
 - polymerization shrinkage, 17
- Direct fiber-reinforced post and core system
 - adhesive bonding agent, 23
 - advantages of, 19, 19b
 - in anterior teeth, 167–169, 167f–169f
 - components of, 22–27
 - core buildup, 25–26
 - description of, 5
 - disadvantages of, 19
 - extracoronar restoration, 26–27
 - fabrication of, 19
 - intraoral fabrication of, 12f
 - luting cement, 23–25
 - metal-ceramic crown with, 14f
 - post material, 22–23
- Direct fiber-reinforced resin system, 5
- Direct-indirect fiber-reinforced post system
 - case study of, 147–152, 147f–152f
 - description of, 20, 22

- Discoloration, cast-metal post as cause of, 3, 4f
- Dislodgment, 7f, 28f, 29, 142
- Dual-cured resin cement
 - autopolymerizing potential of, 84
 - bonding system incompatibility with, 83
 - case studies of, 132, 158, 164, 169, 174, 189
 - composite, 135, 137, 140, 194
 - description of, 12, 83
 - etch-and-rinse adhesives with, 24, 83
 - for extracoronar restorations, 85
 - incompatibility of, with bonding systems, 24
 - indications for, 42
 - injection of, 158–159
 - needle-tube syringe for administration of, 135
 - placement of, 12f
 - self-etching, 155, 166, 185
- Dual-cured self-etching adhesive, 131

E

- EDTA. *See* Ethylenediaminetetraacetic acid.
- Elastic modulus, 17, 41
- Enamel
 - acellular nature of, 65
 - acid etching of, 72–73
 - adhesive surface preparation of, 62
 - aprismatic, 73f
 - characteristics of, 65f–66f, 65–67
 - composition of, 65
 - crystallites of, 66–67
 - dentin and, comparison between, 66–68
 - etching of, 66, 66f
 - hybrid layer of, 73f
 - interrod, 66
 - modulus of elasticity of, 65
 - preservation of, 66
 - surface treatment of, 72–73
 - thickness of, 65, 65f
- Enamel apatite, 66
- Enamel prisms, 65–66, 66f
- Enamel rods, 65–66
- Endocrown, 199–205, 201f–205f
- Endodontic instrumentation, 69
- Endodontic irrigants, 98
- Endodontically treated teeth
 - access opening, sealing of
 - case study of, 177–180, 177f–180f
 - with composite layering technique in ceramic crowns, 181–183, 181f–183f
 - anatomical changes in, 68
 - core stability for, 6–9
 - crown placement for, 26
 - fractures in, 13–17
 - goal for, 177
 - historical beliefs about, 2
 - nonrestorable. *See* Nonrestorable teeth.
 - occlusal forces on, 43

post retention for, 6–9
 predictability of, 40
 rationale for restoration of, 129
 restoration goals for, 13
 survival rates for, 26
 tooth structure conservation for, 9–12, 40
 Enzymatic degradation, of collagen fibrils, 8
 Epoxy polymers, 80
 Esthetic zone, gold post in, 184–187, 184f–187f
 Esthetics, of restorative materials, 13
 Etch-and-rinse adhesives
 concerns about, 85
 description of, 8, 23
 dual-cured resin cement and, 24, 84
 Etching
 acid. *See* Acid etching.
 description of, 72
 selective, 76
 self-etching, 75–76
 total-etching technique, 75, 75f
 Ethanol wet bonding, 8
 Ethylenediaminetetraacetic acid, 8
 ETT. *See* Endodontically treated teeth.
 Eugenol, 69
 Evidence-based dentistry, 210
 Extracoronary restorations
 cementation of, 85
 for cuspal coverage, 26–27, 81
 description of, 26–27
 dual-cured resin cements for, 85
 light-cured resin cements for, 85
 margins of, 16
 types of, 81–82
 Extraction-oriented reconstructive concept, 39

F

Ferrule
 benefits of, 29
 definition of, 27
 partial, 27
 uniform, 27
 Ferrule effect
 biologic width and, 29–30, 30f
 case study of, 102
 definition of, 27, 82
 development of, 27–29, 28f
 inadequate, 29–30, 30f–31f
 methods for establishing
 crown lengthening, 30, 32f–35f, 33, 41
 orthodontic extrusion, 30, 36–39,
 37f–38f, 41–42
 root fracture and, 29
 summary of, 41–42
 Fiber concentration, tensile strength and,
 22, 81
 Fiber-reinforced composites
 adhesive placement of, 42
 description of, 13

luting of
 mechanical properties of
 Fiber-reinforced post systems
 adhesive approach used by, 87
 adhesive interface, 76
 adhesive placement of, 18, 23
 advantages of, 19b
 anisotropic, 17, 80–81
 characteristics of, 80–81
 cleaning of post, 149
 clinical assessments used in selection of, 79
 core buildup for, 81
 factors that affect, 81
 failure of, 6–9, 62
 fractures in, 13
 light-transmitting fibers of, 22f
 on maxillary incisors, 38f
 mechanical properties of, 80
 metal posts versus, 18
 modulus of elasticity of, 17
 post material, 22–23
 prefabricated. *See* Prefabricated fiber-
 reinforced post systems.
 resin cements and, 76f
 retrievability of, 15
 selection of, 79
 surface treatment of, 77–78
 translucent, 24, 84
 types of, 80
 Finishing bur, 137
 Fixed partial denture
 all-ceramic, 162, 163f
 single tooth extraction treated with, 209
 zirconia, 160
 Flexural strength, of post and core systems, 17
 Flowable resin composite, 143–144, 149,
 179f–180f, 190, 247
 Forced eruption. *See* Orthodontic extrusion.
 Fractures
 in fiber-reinforced post systems, 13
 root. *See* Root fracture.
 subgingival, 29, 35f, 193, 196
 tooth fracture with existing crown, “retrofit
 technique” for, 170–172, 170f–172f
 Full-coverage crowns, 81

G

Gel point, 79
 Geller metal cutback technique, 132
 Geller model, 104
 Gingiva
 connective tissue graft, 245
 shadowing of, 3, 4f
 Gingivectomy, 33
 Glass fiber posts
 characteristics of, 23
 description of, 13, 15
 for irregular root configurations, 20

Glass fibers, 81
 Glass-ionomer cements
 classification of, 82
 resin-modified, 82, 142
 Gold post in esthetic zone, replacement of,
 184–187, 184f–187f
 Gutta-percha, 9, 41, 130, 134, 139, 142, 158, 188
 Gutta-percha condenser, 21f

H

Healing abutment, 225, 245–246
 Hybridization, 64
 Hydroxyethyl methacrylate, 75

I

iLumi Super Fiber Post, 42, 93, 143
 Implant(s)
 delayed placement of. *See* Delayed
 implant placement.
 depth gauge for, 229
 indications for, 39
 single anterior, with flapless immediate
 placement, 215–219, 215f–219f
 single posterior, 220–225, 220f–225f
 surgical guide for, 244f, 244–245
 threaded, 229
 tooth replacement uses of, 39
 Implant osteotomy, 223
 Infection control, for light-curing unit, 96, 96f
 Injectable composite technique, for post and
 core development, 153–156, 153f–156f
 Intermolecular cross-linking, 69
 Internal adaptation, 12, 18
 Interprismatic substance, 66
 Interrod enamel, 66
 Intertubular dentin, 67–68, 68f, 71f
 Intraradicular channel, 64, 131
 Intraradicular space, 40–44, 87, 112
 Irradiance, 88–89
 Irradiance value, 89, 92
 Isotropic, 17
 Ivocerin, 90

L

Lamina limitans, 67
 LCU. *See* Light-curing unit.
 LED light source, for light-curing unit, 90, 93,
 95
 Lentulo spiral, 12
 Light-cured resin cements, 24
 Light-curing unit
 “blue-light hazard,” 94–95
 considerations for, 97
 description of, 88
 eye protection with, 97
 fiberoptic posts, 93

infection control for, 96, 96f
 irradiance of, 88–89
 light beam uniformity of, 92–93
 light source for
 distance from light tip to resin, 91–92
 inadequate, 91
 LED, 90, 93, 95
 polywave LED curing light, 90
 single-peak wavelength curing light, 91
 spectral emissions of, 89–90, 89f–90f
 monitoring of, 95–96
 power of, 89
 quartz-tungsten-halogen light, 88, 90
 temperature considerations for, 93–94
 terminology associated with, 88–89
 Long-chain silane monomer, 86
 Luting cements
 composite resin cements, 82–83
 description of, 23–25
 dual-cured, 12

M

Mandibular central incisor, prefabricated
 fiber-reinforced post system in,
 164–166, 164f–166f
 Mandibular crown lengthening, 36f
 Mandibular molars
 delayed implant placement for, 226–232,
 226f–232f
 single posterior implant with delayed
 placement for, 241–249, 241f–249f
 Mandibular premolars, prefabricated fiber-
 reinforced post system in, 134–137,
 134f–137f
 Marginal adaptation, 2
 Masticatory loads, 15
 Matrix metalloproteinases, 8, 42
 Maxillary anterior region restoration, using
 interdisciplinary approach, 157–163,
 157f–163f
 Maxillary central incisor
 atraumatic removal of, 157
 prefabricated fiber-reinforced post system
 in, 193–195, 193f–195f
 resin-bonded bridge for, 211–214, 211f–214f
 subgingival fracture of, 193
 total-etching technique with Ribbond
 reinforcement fiber in, 138–141,
 138f–141f
 Maxillary lateral incisor, prefabricated fiber-
 reinforced post system in, 188–192,
 188f–192f
 Maxillary left canine, prefabricated fiber-
 reinforced post system in, 142–146,
 142f–146f
 Maxillary premolars
 delayed implant placement for, 233–240,
 233f–240f

single posterior implant with delayed
 placement for, 220–225, 220f–225f
 Mechanical interlocking, 70
 Metal cores, 3, 3f
 Metal corrosion, 16
 Metal posts
 corrosion of, 2, 5, 5f
 fiber-reinforced posts versus, 18
 modulus of elasticity of, 41
 occlusal force transmission in, 3, 3f
 prefabricated, 5
 Metal screws, 3
 Metal-ceramic crown
 direct fiber-reinforced post with, 14f
 dislodgment of, 7f
 metal post with, 14f
 restorative failure of, 164
 restorative margin of, 31f
 Methacrylate monomers, 85
 Methacrylate polymers, 80
 10-Methacryloxyloxydecyl dihydrogen
 phosphate, 77
 Microcracks, 17
 Microetching, 108, 175
 Microleakage, 12, 23
 Modulus of elasticity, 5, 5f, 13, 17, 41
 Monoblock, 25, 199–205, 201f–205f
 Multisonic Gentle Wave, 69

N

Nonresorbable graft, 157
 Nonrestorable teeth
 definition of, 210
 mandibular molars
 delayed implant placement for, 226–232,
 226f–232f
 single posterior implant with delayed
 placement for, 241–249, 241f–249f
 resin-bonded bridge for, 211–214, 211f–214f
 single anterior implant for, 215–219,
 215f–219f
 single posterior implant with delayed
 placement for, 220–225, 220f–225f

O

Occlusal forces
 metal core transmission of, 3, 3f, 13
 minimization of, 43
 modulus of elasticity and, 17
 summary of, 43
 Odontoblastic process, 68
 Odontoblasts, 67
 Orthodontic extrusion
 considerations before, 36, 39
 crown lengthening versus, 39
 ferrule effect created by, 30, 36–39,
 37f–38f, 41–42
 indications for, 36

Osseous contouring, 33
 Osteotomy, 227, 229, 236
 Overwet phenomenon, 71
 Ovoid-shaped post and core system, 20, 21f
 Oxygen inhibitor, 110, 239

P

Parallel-sided serrated posts, 5
 Partial thickness flap, 212
 Passive posts, 3
 Peri-implant tissue, 226–227, 240, 248, 249f
 Periodontal-restorative relationship, 29, 30f
 Periodontoblastic matrix, 68
 Periotome, 211, 215
 Peritubular dentin, 67–68, 68f
 Phosphoric acid
 description of, 42
 enamel etching using, 73, 181, 189, 193
 Photon-induced photoacoustic streaming,
 69, 98
 “Pivot crown,” 2
 Plasma-coated fiber ribbon, 167
 Polyethylene woven reinforcement fiber
 description of, 5, 19
 total-etch technique with, 138–141, 138f–141f
 Polymerization shrinkage, 17, 25, 78–79, 87, 98
 Polyvinyl siloxane, 148, 188
 Polyvinyl siloxane impression, 247
 Polywave LED curing light, 90
 Porcelain restorations
 description of, 108
 surface treatment of, 178f
 Post and core systems
 anatomically formed, 42
 antirotational device with, 16
 clinically convenient, 18
 custom-cast, 2
 description of, 41
 dislodgment-related failure of, 28f, 29
 dissimilar metals used in, 2
 failure of, 2, 6, 28f, 40
 fiber-reinforced. *See* Fiber-reinforced post
 systems.
 flexural strength of, 17
 gold, 184–187, 184f–187f
 history of, 2–5
 illustration of, 80
 injectable composite technique, 153–156,
 153f–156f
 light transmission of, 84
 longevity of, 64
 modulus of elasticity of, 5, 5f, 41
 objective of, 2, 43
 “one-visit,” 18
 ovoid-shaped, 20, 21f
 placement guidelines for, 10t
 prefabricated. *See* Prefabricated post and
 core systems.
 rationale for, 2

restorative sequence for, 113–114
 rotational forces, 16
 selection of, 6
 tensile strength of, 17
 tooth-colored, 13
 with zirconia crowns in posterior teeth,
 173–176, 173f–176f

Post channel
 bond strengths in, 24, 84
 bonding in, 64
 cleaning of, 69, 150
 diamond bur preparation of, 6, 41, 113
 dual-cured resin cement injected into, 185
 overpreparation of, 9, 9f, 11
 preparation of, 9
 self-adhesive resin cements in, 84
 smear layer formation from, 74

Post space, 11

Posterior teeth
 biomechanical properties of, 15
 compressive loads on, 15
 endocrowns in, 200
 mandibular
 molars. *See* Mandibular molars.
 zirconia crowns with post and core in,
 173–176, 173f–176f

prefabricated fiber-reinforced post system
 in, 134–137, 134f–137f

zirconia crowns with post and core in,
 173–176, 173f–176f

Post-reinforced crown system
 adhesive integration with, 137, 141
 components of, 7f
 core stability, 6–9
 description of, 6
 maximum post retention, 6–9

Post-retained restorations
 adhesive integration of, 18f
 failure of, 2

Post-retained system, 196–198, 196f–198f

Predentin, 68

Prefabricated fiber-reinforced post systems
 in anterior teeth, 130–133, 130f–133f
 description of, 19–20, 22
 in mandibular central incisor, 164–166,
 164f–166f
 in maxillary central incisor, 193–195,
 193f–195f
 in maxillary lateral incisor, 188–192,
 188f–192f
 in maxillary left canine, 142–146, 142f–146f
 in posterior teeth, 134–137, 134f–137f

Prefabricated post and core systems
 characteristics of, 19–20
 classification of, 3
 composite, 19–20
 composition of, 80
 disadvantages of, 20
 metal posts, 5, 16

nonmetallic
 parallel-sided
 post shapes in, 3
 retention methods for, 3
 tooth structure conservation, 9
 undercuts, 9

Premolars
 endocrowns on, 200
 mandibular, prefabricated fiber-reinforced
 post system in, 134–137, 134f–137f

maxillary
 delayed implant placement for, 233–240,
 233f–240f
 single posterior implant with delayed
 placement for, 220–225,
 220f–225f

“Prevention from extension,” 63

Primers, for total etching, 75

Provisional restorations, 102, 108, 220–221,
 230, 235

Q

Quartz fiber posts, 23, 81

R

Radicular dentin, bonding to, 23

Removable partial denture, 209

Removable wax-ups, 104

Resin cements
 composite, 82–83
 delayed setting of, 87
 disadvantages of, 83
 dual-cured. *See* Dual-cured resin cement.
 excess, removal of, 110
 fiber-reinforced post and, adhesive
 interface between, 76f
 light-cured, 24
 self-adhesive, 25

Resin luting cement, 12

Resin-bonded bridge, for nonrestorable
 tooth, 211–214, 211f–214f

Resin-modified glass-ionomer cements, 82, 142

Resorbable collagen membrane, 223, 243

Restorations
 for cuspal coverage, 26–27, 81
 extracoronaral. *See* Extracoronaral restorations.
 failure of, 6
 objectives of, 209
 principles for, 209
 provisional, 102, 108, 220–221, 230, 235
 summary of, 42–43
 transitional, 217–219, 218f

Restoration-tooth interface
 adhesion at, 70–72
 description of, 112
 stresses at, 78–79, 88, 112

Restorative margins, extracoronaral, 16

Restorative materials
 adhesion at interface of, 70–72
 anisotropic, 17
 antirotation of, 16–17
 core stability criteria for, 6–9
 corrosiveness resistance, 16
 dentin and, interface between, 67
 esthetics of, 13
 internal adaptation, 12, 18
 maximum post retention criteria for, 6–9
 modulus of elasticity of, 17
 optical properties of, 13
 selection of, 6–19, 79
 uninterrupted bonding of, 18–19

“Retrofit technique,” for fractured tooth with
 existing crown, 170–172, 170f–172f

Ribbon reinforcement fiber
 description of, 5, 19
 total-etch technique with, 138–141, 138f–141f

“Richmond crown,” 2

Ridge augmentation, 214

Ridge deficiency, 234

Ridge preservation, 243

Root
 irregular configurations of, 20
 morphological variations in, 11, 41

Root canal sealers, 73

Root fracture
 active post failure caused by, 3
 contributing factors to, 5
 corrosion as cause of, 16
 elevation of, 221
 ferrule effect and, 29
 illustration of, 16f, 222f
 in maxillary premolar, 16f
 post and core restoration failure caused
 by, 28f, 29
 resistance to, 13, 15–17
 vertical, 13

Root perforation, 9f

RPD. *See* Removable partial denture.

S

Selective-etching, 76

Self-adhesive resin cements
 acidity of, 86
 description of, 25, 84–85

Self-cured resin cement
 bonding system incompatibility with, 83
 case study of, 197, 239
 description of, 83
 excess, removal of, 239
 incompatibility of, with bonding systems, 24
 indications for, 42

Self-etch adhesive systems
 adhesion mechanisms of, 85–86
 concerns about, 85
 description of, 8, 23

dual-cured, 131, 155, 185
 fillers used with, 86
 Self-etching primer, 109, 196, 238
 Self-etching technique, 75–76
 Serrated posts, parallel-sided, 5
 Silane, 78, 86, 244
 Silanization, 78
 Single anterior implant, with flapless
 immediate placement, 215–219,
 215f–219f
 Single posterior implant with delayed
 placement
 for mandibular molars, 241–249, 241f–249f
 for maxillary premolar restoration, 220–225,
 220f–225f
 Single-tooth extraction, 209
 Smear layer
 acid-resistant, 6
 description of, 73–74, 74f, 189
 Smear plugs, 74
 Socket preservation, 214
 Specific energy of adhesion, 70
 Split-thickness flap, 34f
 Stainless steel prefabricated metal posts, 5
 Subepithelial connective tissue graft, 234
 Subgingival caries, 37f
 Subgingival fractures, 29, 35f, 193, 196
 Sulcular depth, 31f
 Supracrestal fiberotomy, 42
 Supracrestal tissue, 29
 Surface sealant, 70
 Surface treatment
 of enamel, 72–73
 of fiber-reinforced composite post, 77–78
 Surgical curette, 215
 Surgical guide, 244f, 244–245

T

Tapered implant, 225, 226
 Tensile strength
 fiber concentration and, 22, 81
 of post and core systems, 17, 22
 Threaded implants, 229
 Titanium
 posts, passive oxide layer of, 16
 prefabricated metal posts composed of, 5
 Tooth. *See also specific teeth.*
 isolation of, 97, 109
 preservation of, 39–41
 replacement of, 39–40
 restoration and, interface between. *See*
 Restoration-tooth interface.
 restoration of, 86
 Tooth fracture with existing crown, “retrofit
 technique” for, 170–172, 170f–172f
 Tooth preparation design, biomaterial effects
 on, 86–87
 Tooth structure conservation, 9–12
 Tooth-colored composites, 81
 Tooth-colored posts
 characteristics of, 5
 purpose of, 13
 Total-etching technique
 description of, 75, 75f
 with Ribbond reinforcement fiber, 138–141,
 138f–141f
 Transitional restoration, 217–219, 218f
 Translucent fiber post systems, 24, 84

U

Universal adhesive, 77, 132, 143, 179f, 183
 Universal flowable composites, 25

V

Vertical root fracture, 13
 V-shaped groove condenser, 20

W

Wetting, 70

Z

Zirconia abutment, 230
 Zirconia crowns
 description of, 108
 post and core with, in posterior teeth,
 173–176, 173f–176f
 Zirconia fixed partial denture, 160
 Zirconia posts, 5