
Atlas of
**ORAL and EXTRAORAL
BONE HARVESTING**

Robert E. Marx, DDS

Professor and Chief
Division of Oral and Maxillofacial Surgery
Miller School of Medicine
University of Miami
Miami, Florida

Mark R. Stevens, DMD

Professor and Chair
Division of Oral and Maxillofacial Surgery
School of Dentistry
Medical College of Georgia
Augusta, Georgia



Quintessence Publishing Co, Inc

Chicago, Berlin, Tokyo, London, Paris, Milan, Barcelona,
Istanbul, São Paulo, New Delhi, Moscow, Prague, and Warsaw

Contents

Dedication vi

Preface vii

- 1** History and General Principles 1
- 2** Tibia 7
- 3** Posterior Ilium 19
- 4** Anterior Ilium 39
- 5** Rib 61
- 6** Cranial Bone 79
- 7** Chin 101
- 8** Mandibular Ramus 111
- 9** Maxillary Tuberosity 123
- 10** Recombinant Human Bone Morphogenetic Protein-2/Acellular Collagen Sponge 133
- 11** Bone Marrow Aspiration and Aspirate Concentrate 141

Index 151

Dedication

This book is dedicated to all past, present, and future oral and maxillofacial surgeons in the United States military services. The first chapter briefly chronicles the fundamental wartime contributions of several US military “dental surgeons” (as they were then known) and other surgical specialists in developing the guiding principles of bone healing and harvesting: In the Civil War, Thomas Gunning developed the Gunning splint; in World War I, Robert H. Ivy and Joseph D. Eby innovated the use of block tibia grafts; in World War II, T.G. Blocker Jr and Roy A. Stout introduced iliac crest grafts; and in the Vietnam War, there was a burst of contributions from US Navy oral and maxillofacial surgeons such as James F. Kelley, Robert (Gil) Triplett, Philip J. Boyne, Bill C. Terry, Ronald F. Baker, and Peter Connole, among others. Our profession has been expertly led by such individuals with great vision and innovation.

As former US Air Force oral and maxillofacial surgeons who served in Operation Desert Storm, we understand what it means to be “war ready” and the emphasis it places on reconstruction and rehabilitation of the unique injuries that occur during a military conflict. Today, as in the past, military oral and maxillofacial surgeons assume and discharge that responsibility with great pride and self-sacrifice. And because “only the dead have seen the last of war” (a quote from the philosopher Plato as paraphrased by General Douglas McArthur in 1964), it is inevitable that future military oral and maxillofacial surgeons will do the same. I am confident they will lead the way as their predecessors have. With this book, we salute them all.

Robert E. Marx, Lt Col USAF, DC, Retired

Mark R. Stevens, former Maj USAF, DC

Preface

As a dental student at Northwestern University in the late 1960s aspiring to become an oral surgeon (as they were known at the time), I was allowed to assist in the examination, treatment planning, and follow up of cancer and tumor patients at Cook County Hospital in Chicago. I learned a great deal observing the lengthy but precise surgeries that were performed by ablative surgeons in the anatomically complex areas of the jaws and neck. However, reconstruction of these patients was rare; most were left deformed and functionally compromised, suffering from jaw deviations, malocclusions, and drooped lips and shoulders and plagued by drooling and other maladies. The main rationale for leaving these people unreconstructed was to spare them the pain and permanent limp that would inevitably result from harvesting bone from the anterior hip. “The patient is better off without a jaw than crippled” was the explanation I was given again and again. As a consequence of these experiences, I have dedicated my career to developing techniques that reduce morbidity related to jaw reconstruction at both the recipient and donor sites so that the outcome outweighs the drawbacks.

I first met my coauthor, Mark Stevens, when he was a resident under my direction in the Air Force training program at Wilford Hall United States Air Force Medical Center; later I recruited him to join my faculty at the University of Miami Miller School of Medicine, where we committed ourselves to refining the anatomic knowledge and surgical techniques related to harvesting bone from the posterior ilium, anterior ilium, cranium, and tibia. From chapter 1 through chapter 9, this book presents everything we have learned and the techniques we developed in a logical, step-by-step fashion, including indications, utility, contraindications, cautions, anatomy, surgical technique, drains and dressings (where indicated), postoperative care, and complications. The anatomy and surgical techniques are beautifully illustrated by one of the great medical artists of our time, Dr Gerald Harper, a fellow oral and maxillofacial surgeon. Our own supporting case photographs complement his fine work.

We also had an eye on the ultimate goal of jaw reconstruction without open bone harvesting altogether. Consequently, as readers progress to chapters 10 and 11, they are introduced to the tantalizing potential for no harvest site morbidity. The use of recombinant human bone morphogenetic protein-2 (rhBMP-2) combined with autologous stem cells derived from bone marrow aspirate concentrations (BMAC) has already proven successful in reconstructing several patients with large continuity defects with no open bone harvest. These

advances in biotechnology may play a significant role in the future of reconstructive jaw surgery.

It is our hope that the techniques presented in this atlas help other surgeons provide reconstructive jaw surgery to more individuals in need of it and at the same time reduce their pain, swelling, disability, and time away from work and family.

Robert E. Marx, DDS

Chapter Four

Anterior Ilium

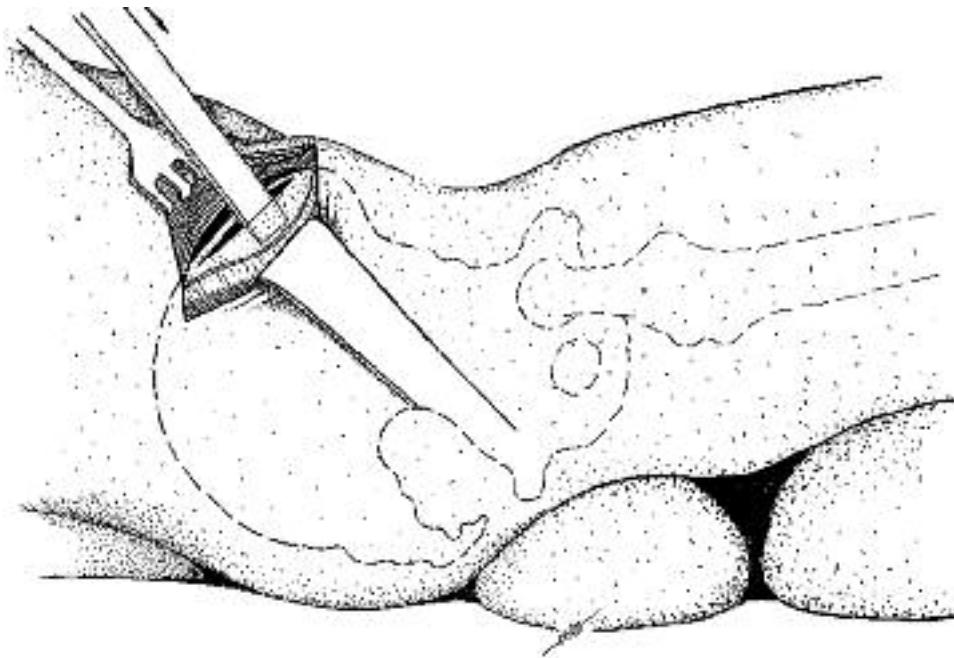


Fig 4-18 Harvesting cancellous marrow using medial trap door approach.

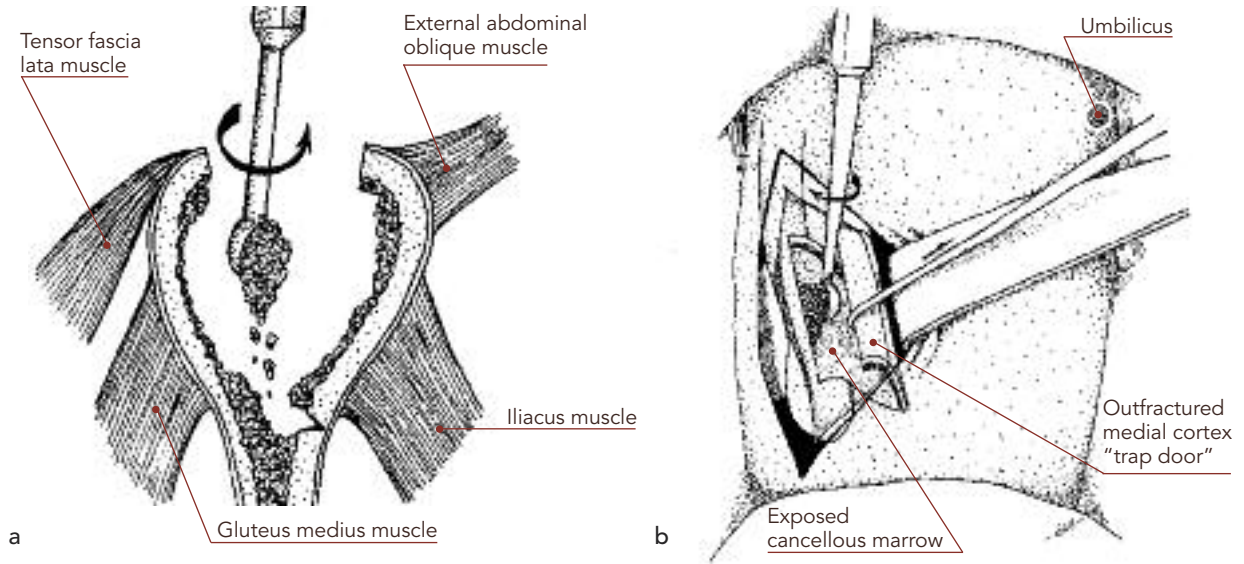
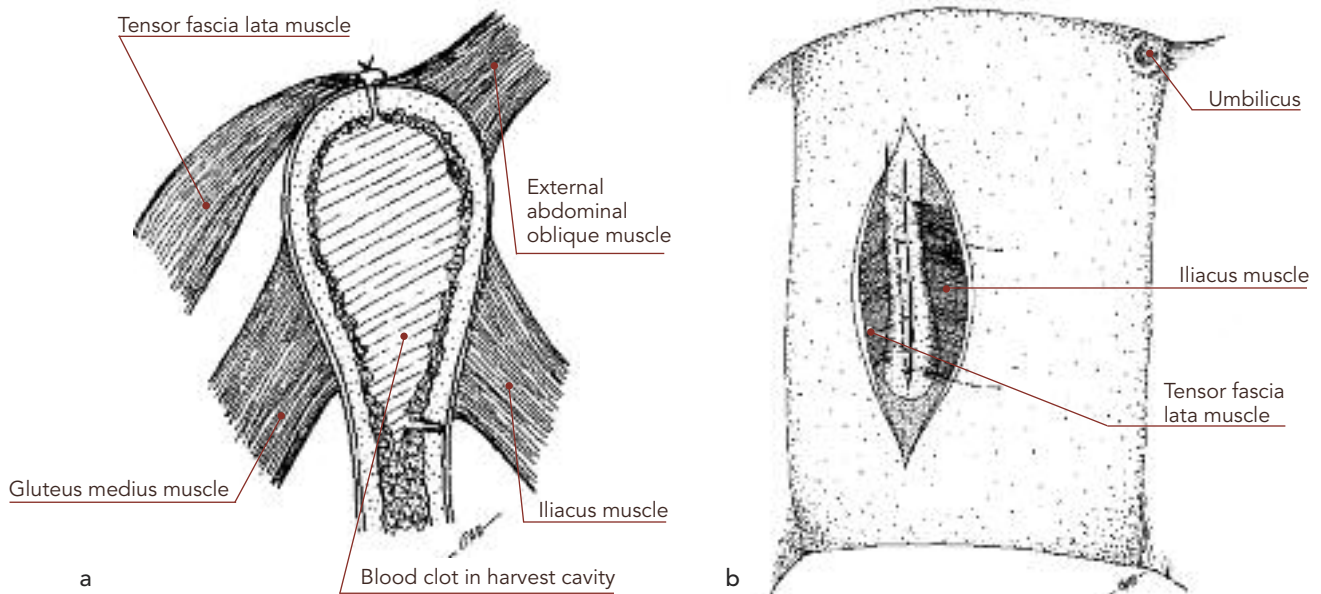
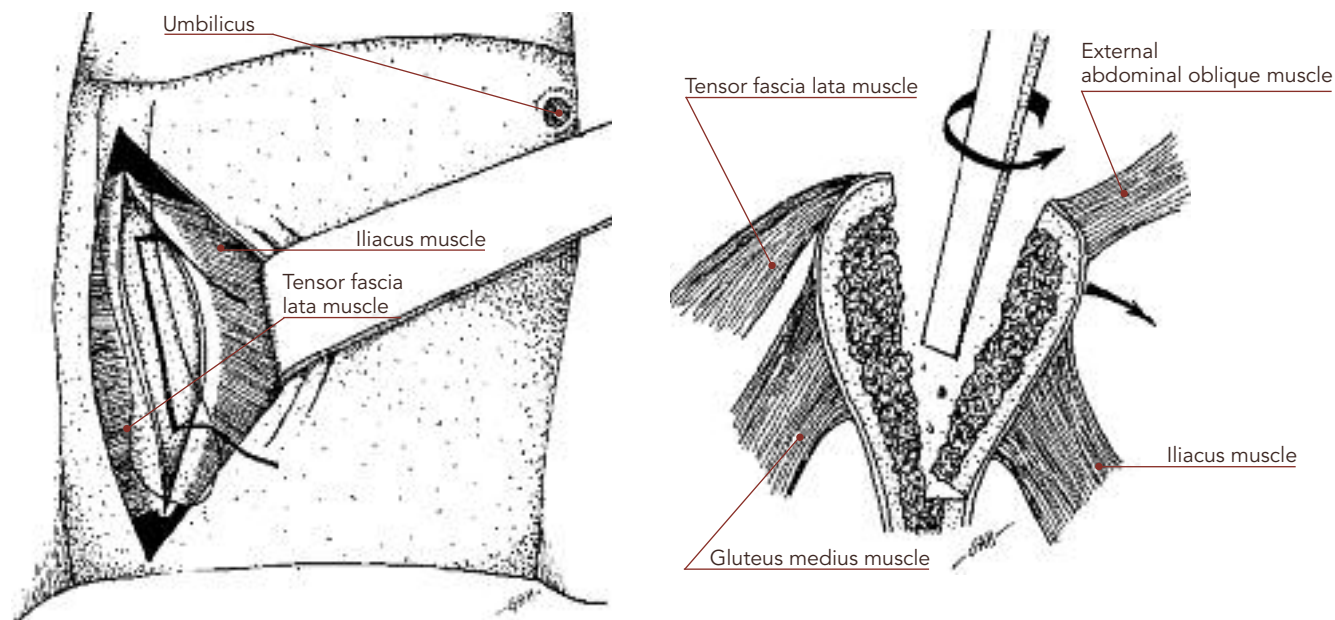


Fig 4-19 Closure of the periosteum and muscle fascia will reposition the outfractured trap door.



Figs 4-16 and 4-17 Medial trap door approach to the anterior ilium.



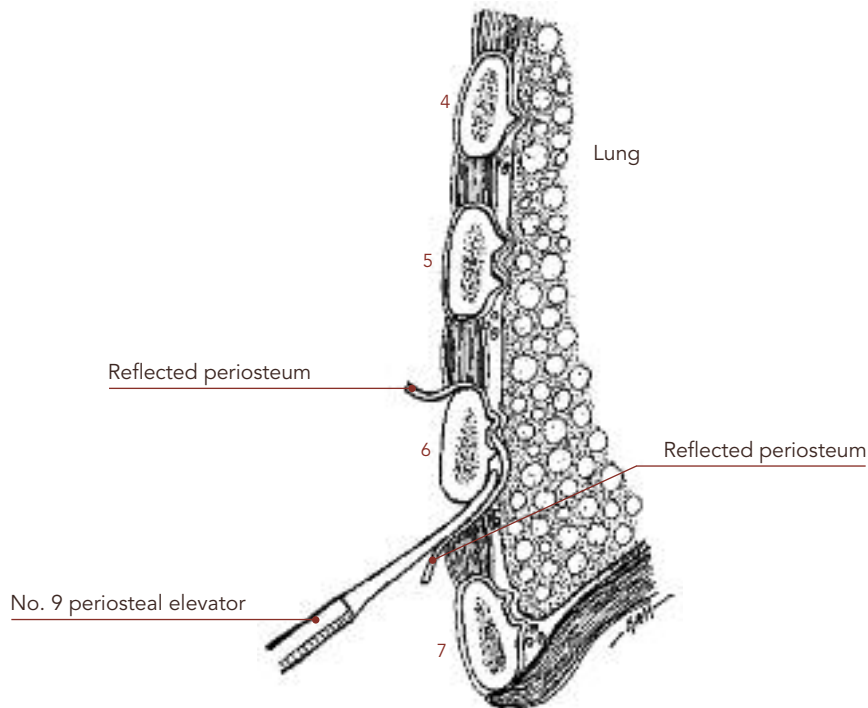
Medial trap door approach

Once the midcrestal periosteal incision is made, an osteotome or reciprocating saw is inserted directly on the bone for a midcrestal split. To complete the trap door concept, two vertical cortical osteotomies are also made through the medial cortex between the muscle fibers of the iliacus muscles. The anterior vertical osteotomy is placed 2 cm posterior to the anterior superior spine and the posterior vertical osteotomy 7 cm posterior to the anterior superior spine in the general area of the tubercle of the anterior ilium (Fig 4-16), creating a 5-cm length of graft site. These osteotomies can be accomplished with either a reciprocating saw or a one-half-inch osteotome. The osteotome is then malleted through the midcrestal osteotomy to a depth of 5 cm and levered medially to outfracture the medial cortex (Fig 4-17). This will expose more cancellous marrow than the clamshell approach but, like the clamshell, is not designed to yield a corticocancellous block. The exposed cancellous marrow is gouged or curetted from the site and from the outfractured medial cortex (Fig 4-18). The medial cortex, with its muscle attachments undisturbed, is repositioned and usually can be stabilized with periosteal sutures (Figs 4-19). If not, wire fixation can be used.

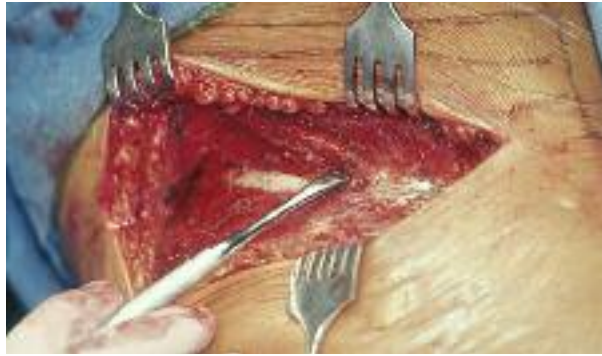

Fig 5-11 For best results, reflect the periosteum of the rib using a standard periosteal elevator and begin on the superficial surface of the rib.

Fig 5-12 A standard periosteal elevator can be used to reflect the rib periosteum on its deep surface without tearing the parietal pleura.



throughout the entire procedure (Fig 5-11). These instruments will separate the periosteum even from these bony projections without creating tears (Fig 5-12). After completing the periosteal elevation, transect through the cartilage, leaving 3 mm of cartilage on the rib in adults and children (Figs 5-13 and

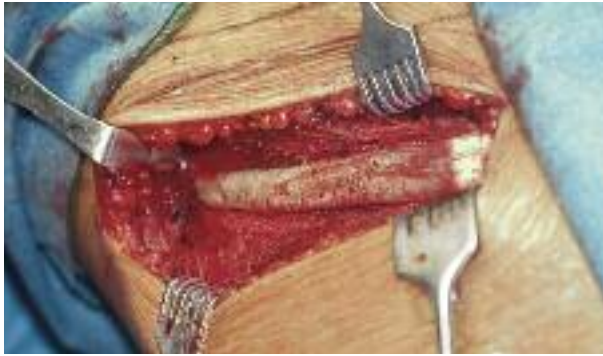

Fig 5-13 A full length of the right sixth rib is exposed to the costochondral junction.

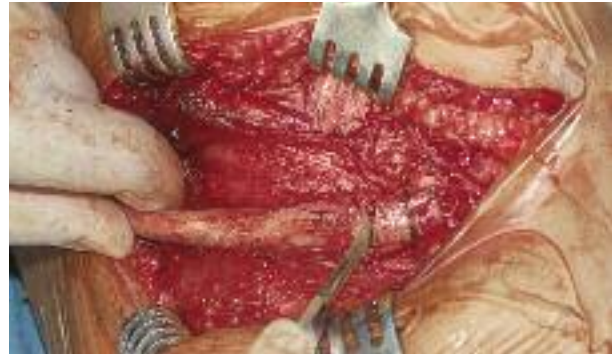
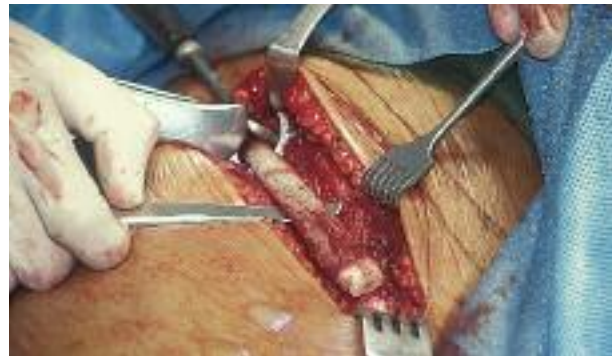
Fig 5-14 It is best to transect through the cartilage first, allowing 3 mm of cartilage to remain on the rib.

Fig 5-15 For elevation, place a Seldin elevator under the rib to facilitate transection of the proximal end with either a rib cutter or a reciprocating saw, thus delivering the harvested rib.



5-14). This effort can also be further facilitated by placing a Seldin elevator under the rib and elevating the rib slightly (Fig 5-15).

Once the desired length of rib is reflected from its periosteum, the rib is cut and delivered as a graft. This can be accomplished with standard rib cutters (see Fig 5-15) or via a reciprocating saw with protection at the deep surface. The sharp ends of the resection margin should be rounded, and small periosteal bleeding vessels that are usually present should be cauterized.

Closure

Closure is accomplished without a drain. The closure begins with the periosteal incision, which is closed with a 3-0 resorbable suture (Fig 5-16), followed by the fascia between the pectoralis major and the rectus abdominis muscles; the subcutaneous level; and then the skin surface (Fig 5-17).