
Daniele Manfredini

Current Concepts on Temporomandibular Disorders

 **QUINTESSENCE PUBLISHING**

London, Berlin, Chicago, Tokyo, Barcelona, Istanbul, Milan, Moscow,
New Delhi, Paris, Beijing, Prague, São Paulo, Seoul and Warsaw

Preface

When the idea to bring together some of the most renowned experts in the field to give form to a work on the state-of-the-art knowledge of temporomandibular disorders (TMD) came to my mind, I was inspired to pursue that dream. But then I realized how difficult a task I was undertaking and doubts started to cloud my mind.

Classically, the TMD field has been characterized by a paradigmatic contrast between the guidelines provided by the scientific community and beliefs of clinical practitioners, who still look at dental occlusion as the main etiopathogenetic factor and the primary therapeutic target. The ambitious aim of this work is to keep on seeking a synthesis between these two cultures, as has already been attempted by some other recent textbooks on this subject. So the focus of all the contributors has been on the need to present scientifically sound information in a clinically useful manner.

This book will probably be one of the last in which the term “temporomandibular disorders” is used, since terminological specifications will hopefully be introduced in the near future, as soon as there is an improvement in knowledge about the pathophysiology of these disorders. Indeed, the absence of a validated pathophysiological model for many TMD symptoms has led to the adoption of this generic term to group together signs and symptoms with different etiopathogenesis and, more importantly, to adopt a symptomatic and common approach towards the management of diseases

of the temporomandibular joint and muscles. For this reason, the part of the book dedicated to etiology of TMD is the only one in which specific chapters are devoted to the supposedly different groups of disorders, namely muscle disorders, disc displacements, and arthrosis/arthrititis. The parts on diagnosis and management reflect the current view that the approach to TMD patients is seldom different for joint and muscle symptoms, to the point that only a minority of treatment modalities are exclusively indicated for a specific disorder.

Along with this underlying premise, the main thrust of the book is the medically based view of TMD, which cannot be considered pertinent to the dental profession alone.

All the chapters reflect the considerable efforts of the contributors to capture the reader's attention without abandoning their roles as academicians, scientists, and researchers. I have learnt that the greatest personalities are also the most modest ones, and this adventure has confirmed this for me. I have had the honor to work with 45 outstanding world-renowned authors in the TMD and orofacial pain field, and none of them has ever refused to exchange opinions, accept advice, or provide suggestions. To all of them I give my most grateful thanks for agreeing to be part of this project, one of the most exciting of my professional career to date.

Together we hope that our efforts will be appreciated by the heterogeneous community of TMD readers and practitioners.

To Debora, Aurora, Giacomo

Love, Life, Smile

Contents

Part I Fundamentals

- 1. Anatomy of the Temporomandibular Joint and Masticatory Muscles** 3
A. Bermejo-Fenoll
- 2. TMD Classification and Epidemiology** 25
D. Manfredini and L. Guarda Nardini
- 3. TMD as a Chronic Pain Disorder** 41
T. Suvinen

Part II Etiology

- 4. Etiopathogenesis of Muscle Disorders** 61
G.M. Murray and C. Peck
- 5. Etiopathogenesis of TMJ Disc Displacements** 81
D. Paesani
- 6. Temporomandibular Joint Osteoarthritis** 111
D.W. Nitzan and A. Roisentul
- 7. Bruxism and Temporomandibular Disorders** 135
D. Manfredini and F. Lobbezoo
- 8. Future Perspectives in TMD Pathophysiology** 153
R. Peretta and D. Manfredini

Part III Diagnosis

| | |
|--|-----|
| 9. Introduction to TMD Diagnosis | 171 |
| <i>D. Manfredini</i> | |
| 10. Clinical Assessment | 179 |
| <i>M. Schmitter</i> | |
| 11. Psychosocial Assessment | 191 |
| <i>D. Manfredini</i> | |
| 12. Imaging of the Temporomandibular Joint | 207 |
| <i>A. Petersson</i> | |
| 13. Instrumental Approach | 223 |
| <i>K. Baba, Y. Ono and G. T. Clark</i> | |
| 14. Fibromyalgia | 237 |
| <i>K. Sipilä</i> | |
| 15. Differential Diagnosis of Orofacial Pain | 247 |
| <i>R.M.A. Leeson</i> | |
| 16. Headache and Temporomandibular Disorders | 263 |
| <i>F. Mongini</i> | |
| 17. Relationship between Otologic and TMD Symptoms | 275 |
| <i>E.F. Wright</i> | |
| 18. Malocclusion and Body Posture | 283 |
| <i>A. Michelotti and M. Farella</i> | |
| 19. Perspectives in Clinical Diagnosis of Temporomandibular Disorders | 295 |
| <i>R. Emshoff</i> | |

Part IV Management

| | |
|--|-----|
| 20. Fundamentals of TMD Management | 305 |
| <i>D. Manfredini</i> | |
| 21. Behavioral Treatment Approaches to Temporomandibular Joint and Muscle Disorders | 319 |
| <i>R.J. Gatchel</i> | |
| 22. Physical Therapy | 327 |
| <i>P. Nicolakis, V. Fialka-Moser</i> | |
| 23. Pharmacologic Management | 339 |
| <i>C.M. Rizzatti-Barbosa and M.C. Ribeiro-Dasilva</i> | |
| 24. Occlusal Therapy of Temporomandibular Pain | 359 |
| <i>J.C. Türp and H.J. Schindler</i> | |
| 25. Placebo Effect | 383 |
| <i>G. Mauro, G.M. Macaluso, C.S. Greene, G. Goddard and E. Manfredi</i> | |
| 26. TMJ Arthrocentesis | 393 |
| <i>L. Guarda Nardini and G. Ferronato</i> | |
| 27. TMJ Major Surgery | 403 |
| <i>G. Dimitroulis</i> | |
| 28. Prosthetic Rehabilitation in TMD Patients | 417 |
| <i>J.A. De Boever, A. De Laat</i> | |
| 29. Orthodontics in TMD Management | 429 |
| <i>D.J. Rinchuse and S. Kandasamy</i> | |
| 30. Management of Bruxism | 447 |
| <i>E. Winocur and F. Lobbezoo</i> | |
| 31. Integration of Research into Clinical Practice | 459 |
| <i>D. Manfredini</i> | |
| 32. Ethical and Legal Considerations | 469 |
| <i>M.B. Bucci</i> | |
| 33. Treatment of TMD: Think Twice! | 483 |
| <i>F. Lobbezoo, C.M. Visscher and M. Naeije</i> | |
| Index | 487 |

List of Contributors

Kazuyoshi Baba DDS, PhD
Chair and Professor, Department of
Prosthodontics, School of Dentistry, Showa
University, Japan

Ambrosio Bermejo-Fenoll MD, DDS, PhD
Professor, Department of Dermatology,
Stomatology, Radiology and Physical
Medicine, Faculty of Medicine and
Odontology, University of Murcia, Spain

Jan A De Boever DDS, DMD, PhD
Professor Emeritus, Gent University, Belgium

Brady M Bucci MD
Forensic odontologist, private practice,
La Spezia, Italy

Glenn T. Clark DDS, MS
Professor, Division of Diagnostic Sciences,
University of Southern California
School of Dentistry, Los Angeles, USA

Antoon De Laat DDS, PhD
Professor, Department of Oral and
Maxillofacial Surgery, School of Dentistry, Oral
Pathology and Maxillofacial Surgery, Catholic
University of Leuven, Belgium

*George Dimitroulis MDSc, FDSRCS(Eng),
FFDRCS(Irel), FRACDS(OMS)*
Head of Maxillofacial Surgery, Department of
Surgery, St Vincent's Hospital, University of
Melbourne, Australia

Rüdiger Emshoff Dr Med, Dr (H)
Associate Professor, University Clinic of Oral
and Maxillofacial Surgery, Innsbruck Medical
University, Austria

Mauro Farella DDS, PhD
Assistant Professor, Orthodontics and TMD
Clinic, Department of Dental, Oral and
Maxillofacial Surgery, University of Naples
Federico II, Italy

Giuseppe Ferronato MD, DDS
Professor and Head, Department of Oral and
Maxillofacial Surgery, University of Padova,
Italy

Veronika Fialka-Moser MD
Professor, Department of Physical Medicine
and Rehabilitation, AKH Wien, Medical
University of Vienna, Austria

Robert J Gatchel PhD, ABPP
Professor and Chairman, Department of
Psychology, College of Science, University of
Texas at Arlington, USA

Greg Goddard DDS
Associate Clinical Professor (retired),
University of California at San Francisco, USA

Charles S Greene DDS
Clinical Professor and Director of Orofacial
Pain Studies, Department of Orthodontics,
College of Dentistry, University of Illinois in
Chicago, USA

*Sanjivan Kandasamy BDS, BScDent,
DocClin-Dent, MOrthoRCS*
Senior Lecturer, Department of Orthodontics,
Dental School, University of Western
Australia, Perth, Australia

*Rachel M A Leeson BDS, MSc, PhD, FDS,
RCS, FHEA*
Specialist in Oral Surgery, Maxillofacial and
Oral Surgery Department, Eastman Dental
Hospital, University College London

Frank Lobbezoo DDS, PhD
Professor, Department of Oral Kinesiology,
Academic Centre for Dentistry Amsterdam
(ACTA), University of Amsterdam, and VU
University Amsterdam, The Netherlands

Guido M Macaluso MD, DDS, MDS
Professor, Section of Odontostomatology,
Faculty of Medicine, University of Parma, Italy

Edoardo Manfredi DDS
Researcher, Section of Odontostomatology,
Faculty of Medicine, University of Parma, Italy

Daniele Manfredini DDS
Visiting Professor, TMD Clinic, Department of
Maxillofacial Surgery, University of Padova,
Italy

Giovanni Mauro MD, DDS, PhD
Visiting Professor, Section of
Odontostomatology, Faculty of Medicine
University of Parma, Italy

Ambra Michelotti MD, DDS, PhD
Professor, Orthodontics and TMD Clinic,
Department of Dental, Oral and Maxillofacial
Surgery, University of Naples Federico II, Italy

Franco Mongini MD
Professor and Director, Section for
Headache and Facial Pain, Department of
Clinical Pathophysiology, University of Torino,
Italy

Greg M Murray BDS, MDS, PhD, FRACDS
Professor, Faculty of Dentistry, University of
Sydney, Australia

Machiel Naeije PhD
Biophysicist, Professor and Chair, Department
of Oral Kinesiology, Academic Centre for
Dentistry Amsterdam (ACTA), University of
Amsterdam, and VU University Amsterdam,
The Netherlands

Luca Guarda Nardini MD, DDS
Visiting Professor and responsible for TMD
Clinic, Department of Maxillofacial Surgery,
University of Padova, Italy

Peter Nicolakis MD
Professor, Department of Physical Medicine
and Rehabilitation, AKH Wien, Medical
University of Vienna, Austria

Dorrit W Nitzan DMD
Professor, Department of Oral and
Maxillofacial Surgery, Faculty of Dental
Medicine, Hebrew University-Hadassah
School of Dental Medicine, Jerusalem, Israel

Yasuhiro Ono DDS, PhD
Assistant Professor, Department of
Prosthodontics, School of Dentistry, Showa
University, Japan

Daniel Paesani DDS
Professor, School of Dentistry, University of
Salvador/AOA, Buenos Aires, Argentina

Christopher C Peck BDS, MScDent, PhD
Associate Professor, Faculty of Dentistry,
University of Sydney, Australia

Redento Peretta MD, DDS, PhD
Visiting Professor, Department of Maxillofacial
Surgery, University of Padova, Italy

Arne Petersson DDS, Odont dr
Professor, Department of Oral and
Maxillofacial Radiology, Faculty of
Odontology, Malmö University, Sweden

*Margarete Cristiane Ribeiro-Dasilva DDS, MS,
PhD*
Postdoctoral Fellow, College of Dentistry,
University of Florida, USA

Donald J Rinchuse DMD, MS, MDS, PhD
Clinical Professor of Orthodontics, School of
Dental Medicine, Department of
Orthodontics, University of Pittsburgh, USA

Celia Marisa Rizzatti-Barbosa DDS, MS, PhD
Professor, Department of Prosthesis and
Periodontology, Dental College of Piracicaba,
State University of Campinas (Unicamp), Brazil

Alejandro Roisentul DDS
Head, Unit of Oral and Maxillofacial Surgery,
Ziv Governmental Hospital, Safed, Israel

Hans J Schindler DDS, Dr Med Dent Habil
Associate Professor, Department of
Prosthodontics, University of Heidelberg, and
Biomechanics Research Group, University of
Karlsruhe, Germany

Marc Schmitter DMD
Professor, Department of Prosthodontics,
Dental School, University of Heidelberg,
Germany

Kirsi Sipilä DDS, PhD
Senior Lecturer, Department of
Stomatognathic Physiology and Prosthetic
Dentistry, Institute of Dentistry, University of
Oulu, Finland

Tuija Suvinen DDS, PhD
Docent and Senior Scientist, Department of
Stomatognathic Physiology, Institute of
Dentistry, University of Turku, Finland

Jens C Türp DDS, Dr Med Dent Habil
Professor, Clinic for Reconstructive Dentistry
and Temporomandibular Disorders, Dental
School, University of Basel, Switzerland

Corine M Visscher PT, PhD
Epidemiologist, Assistant Professor,
Department of Oral Kinesiology, Academic
Centre for Dentistry Amsterdam (ACTA),
University of Amsterdam, and VU University
Amsterdam, The Netherlands

Ephraim Winocur DMD
Director, Orofacial Pain Clinic, Goldschleger
School of Dental Medicine, University of Tel
Aviv, Israel

Edward F Wright DDS, MS
Associate Professor, Department of
Restorative Dentistry, University of Texas
Health Science Center at San Antonio, USA

PART I

FUNDAMENTALS

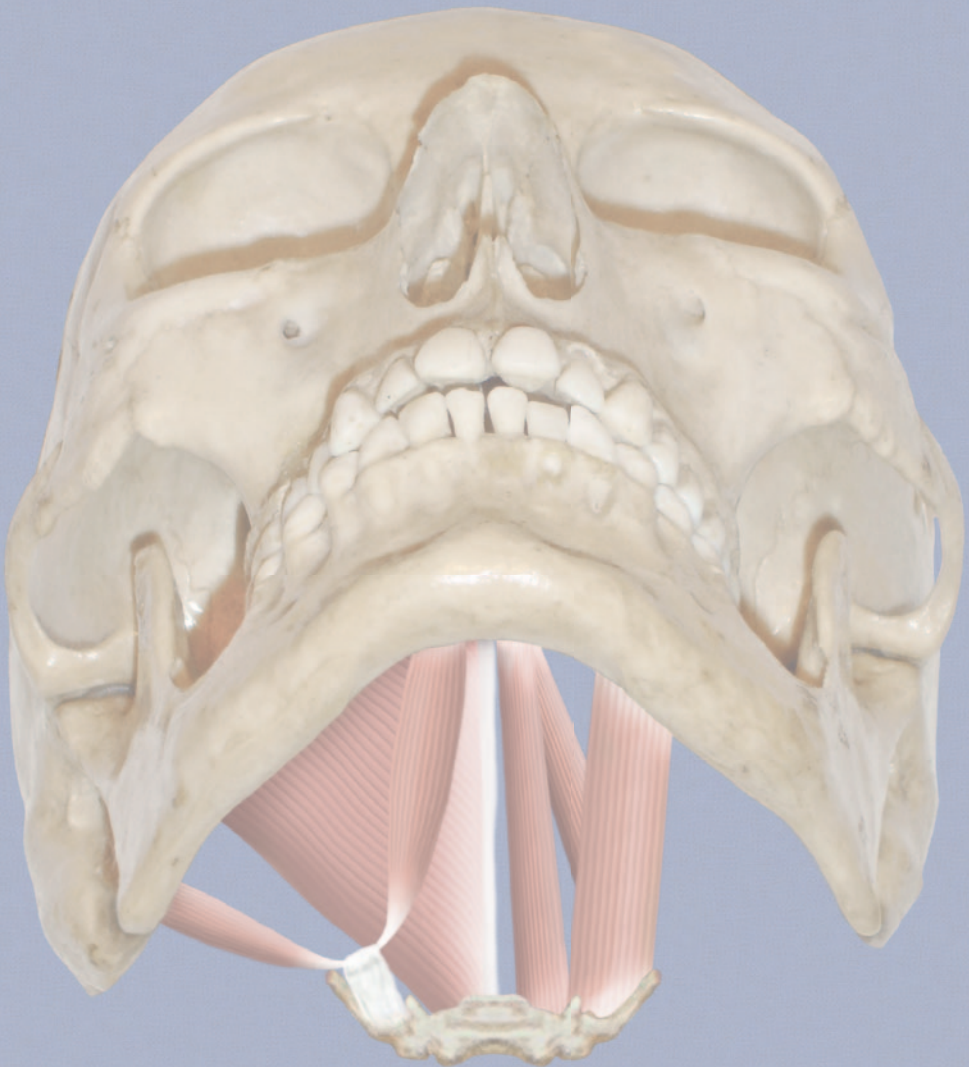


Table 8-2 Elements in biomechanical analysis of the temporomandibular joint.

| Element | Characteristics | Condyle | Glenoid fossa | Disc |
|----------------------------|--------------------|----------------------------------|---------------|----------------|
| Body | Geometry | Section | Height | Convexity |
| | Material | Length bone | Depth bone | Fibrocartilage |
| Load features | Force vectors | Static Dynamic fatigue cycles | | |
| Systems of body constraint | Degrees of freedom | | | |

venience, in the remaining sections of the chapter, a brief description of the differences between forces exerted during function and during parafunction will be provided.

In addition, another element that should be introduced in the analysis is the number of degrees of freedom that characterize condylar movements under loading conditions.

In the following sections, the two conditions leading to joint overload, ie structural defect of the joint or abnormal joint load, will be described in detail with a focus on the mechanisms of load transfer on the joint tissues.

Morphology of the Structurally Defective TMJ

There is much debate about the definition and description of the normal condylar morphology, and the many three-dimensional reconstructions proposed over the years, despite their appeal, can only be considered speculative (Figs 8-1a to 8-1c).

Thus, the identification of a typical joint morphology that is not suitable to bear loads has to start with the consideration and combination of both engineering and medical aspects. There is a considerable amount of orthodontic and maxillofacial literature showing that subtle, short, and posteriorly sloping condyles are a risk factor for the development of degenerative changes within the TMJ.^{30,31} From a clinical viewpoint, such observations are well known

to maxillofacial surgeons who have treated skeletal class II patients with a mandibular advancement. Post-surgically, the stretching of the suprahyoid muscles induces a strong tensile force in the muscle, which is a risk factor for degenerative joint disease in those patients who have condyles with such structural characteristics.³² Similar consequences may be seen in such patients also after surgery for internal mandibular ramus fixation.^{33,34} These observations have contributed to the question of whether the so-called “idiopathic condylar resorption”, which shares many features with the other degenerative changes described as osteoarthritis,³⁵ is actually a long-term consequence of orthognathic surgery performed in patients with a peculiar condylar morphology. In summary, a small condyle is morphologically at risk of developing degenerative changes if it is exposed to excessive loads as a consequence of orthognathic surgery (Figs 8-2a, 8-2b).

And what about such a condylar morphology in patients who do not undergo orthognathic surgery? This question may find an answer in a philosophical analysis of the TMD–occlusion relation. As reported in many other sections of this book, studies on this issue have shown a weak association between TMD and occlusion, mainly in cases of gross dental occlusal abnormalities, such as a large horizontal overlap, ie overjet, and a decreased vertical overlap, ie overbite.^{36,37} The main shortcoming of any investigation trying to assess the relation between occlusion and TMD is the absence of any assessment of the skeletal morphology, the evaluation of which should be of much interest

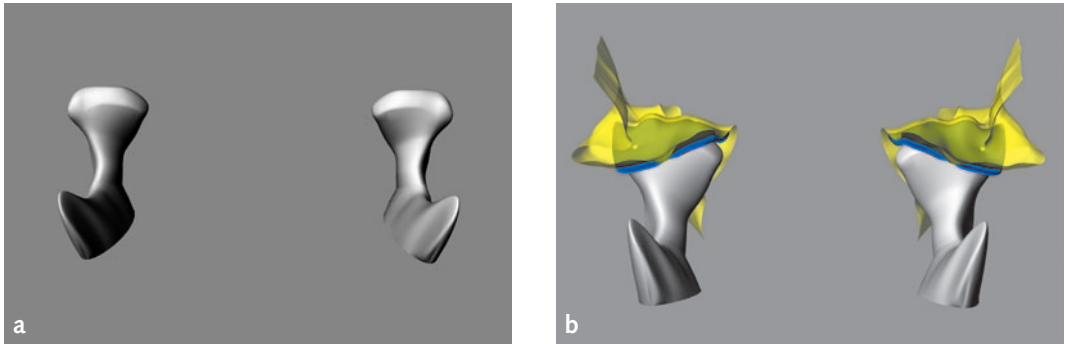


Fig. 8-1a–c Example of normal condylar position and joint morphology (tomography-derived three-dimensional model, DICOM).

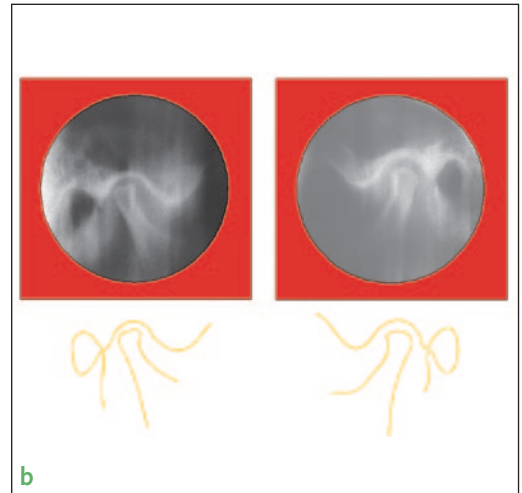
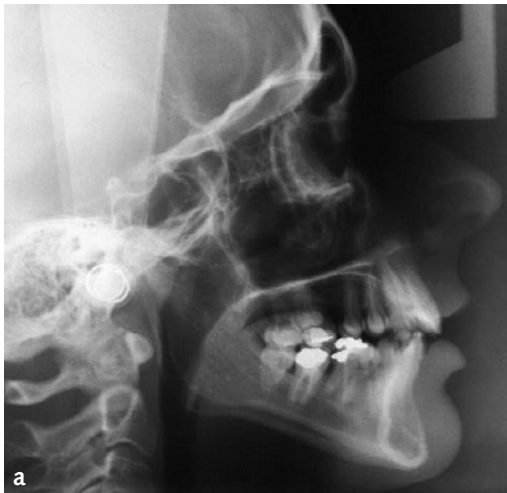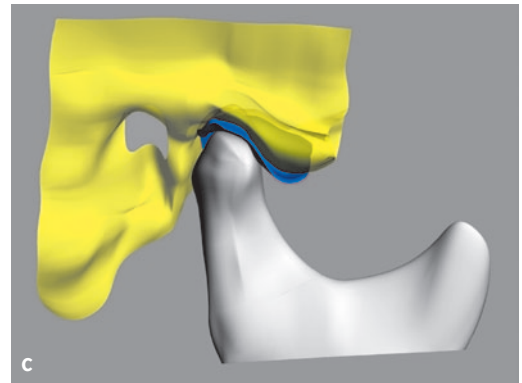


Fig. 8-2a, b Lateral cephalometric radiograph, and corrected oblique transcranial radiographs and tracings of small condyles in a patient with a large horizontal overlap.

should be easy to learn, cost-effective, internationally accepted, available in different languages, and continually improving. Thus, on the one hand, non-essential features should be eliminated, and on the other, essential features should be emphasized and must not be eliminated. However, many systems emphasize physical findings and disregard psychosocial variables, although the importance of these variables in the development and maintenance of (painful) TMD has been demonstrated. Additionally, the identification of other clinical examination procedures is challenging and for some diagnostic systems, little is known about the scientific characteristics (reliability etc.).

In the following sections, several aspects of a clinical TMD examination are described. For an instrumental approach to TMD see Chapter 13.

Dental/Medical History

In TMD patients, special attention should be paid to the history as important information can be gathered. Beside the knowledge of trauma⁹ and other potentially harmful events,¹⁰ the history taking might uncover valuable information about the onset of the TMD, its progression, and other particular information about the patient.¹¹ This information could enhance the clinical findings and lead to a more reliable diagnosis, and could consequently help to plan the most effective therapy concept. Thus, enough time should be provided for this important aspect in the clinical assessment of TMD.

Palpation of the Muscles

The assessment of pain during the palpation of masticatory muscles is an important aspect in diagnosing myofascial pain. Thus, almost all available clinical examination protocols include the palpation of jaw muscles, although the number and the location of the included palpated muscles are different. Some of the

most important muscles which are included in almost all examination protocols are depicted in Figure 10-3. The palpation techniques (including pressure etc.) are quite different. (Fig. 10-4 shows palpation of the different muscles being carried out.) These factors confound the comparability of different examination protocols with respect to muscular findings. Moreover, some examination protocols recommend palpating the lateral pterygoid muscle, which is not directly palpable.¹²

Several studies have assessed the reproducibility of the muscle palpation and found acceptable to good agreement between the examiners,¹³⁻¹⁵ although the reliability of the palpation of intraoral muscles might be lower than for extraoral muscles. However, it has also been demonstrated that calibration improves the reliability¹⁴ of standardized clinical examination procedures. Another study found that in this scenario, the calibration of the examiners is more important than professional experience.⁵ Thus, training on letter scales (Fig. 10-5) is recommended; retraining of examiners might improve the reliability even more.^{4,16} The use of pressure algometers (Fig. 10-6) has been assessed in several studies and it seems to improve the reliability of the palpation,^{17,18} justifying the use of algometers in clinical and experimental studies.

Joint Palpation

Pain on palpation might be an indicator of a pathologic process in the temporomandibular joint and is included in several TMD examination protocols (Fig. 10-7, Fig. 10-8). The results for reliability are comparable with those for muscle palpation in studies. However, the differentiation between muscle and joint pain might be difficult for the patient because of the proximity of the temporomandibular joint and nearby muscles¹⁹ and the presence of trigger points.²⁰ Thus, the results of palpation have to be interpreted with great care.

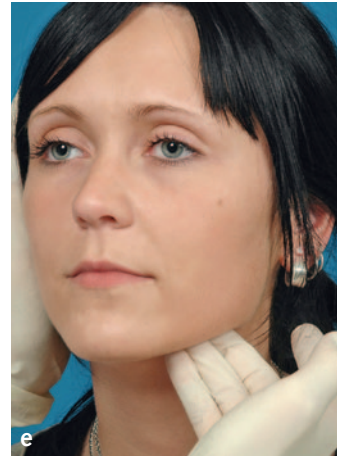
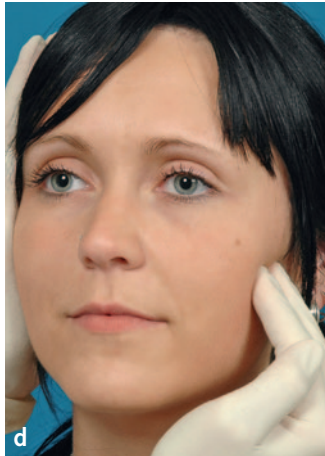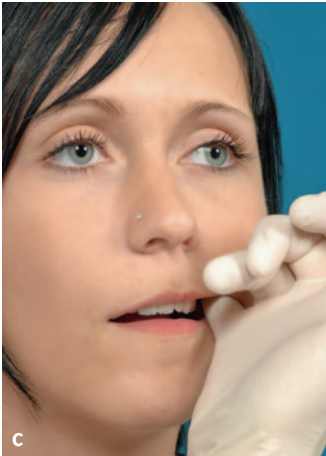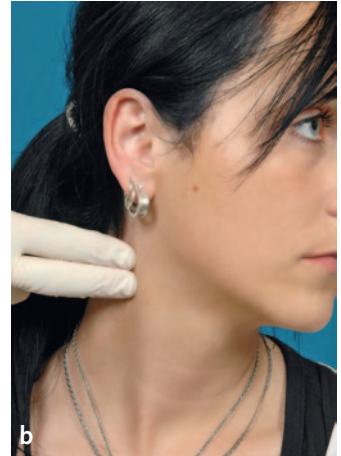
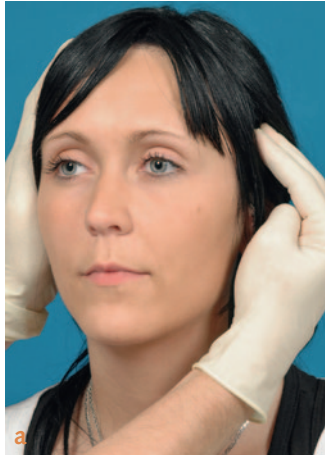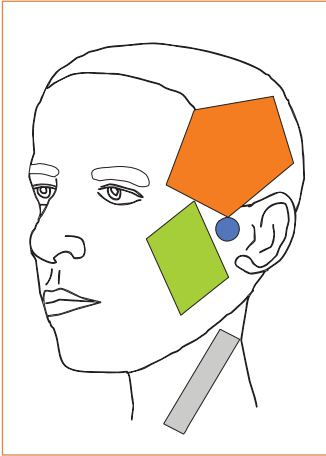


Fig. 10-3 (top left) Location of the most important muscles that are included in an examination protocol for TMD.

Fig. 10-4a-e Palpation of the different jaw muscles included in a TMD clinical examination.



Fig. 10-5 Calibration of palpation pressure using letter scales.



Fig. 10-6 Pressure algometers may be useful tools to improve the reliability of muscle palpation.